

Pterijyum Cerrahisine Bağlı Kornea Perforasyonunda Tektonik Kornea Greftlemesi

Tectonic Corneal Grafting After Corneal Perforation due to Pterygium Surgery

Melis Palamar Onay, Sait Eğrilmez, Ayşe Yağcı

Department of Ophthalmology, Ege University Faculty of Medicine, Izmir, Turkey

Summary

To report three cases of corneal perforation after pterygium surgery with primary conjunctival closure and intraoperative mitomycin C, and its treatment with corneal grafting. Three patients, who had undergone pterygium excision with primary conjunctival closure and intraoperative mitomycin C elsewhere, were referred to our clinic for corneal perforation. Nasally located corneal perforation was evident in all cases. Corneal grafting was performed to repair the perforation. The grafting was successful in all cases and no complication or need for further treatment was observed. Corneal perforation is a rare complication of pterygium surgery. Tectonic corneal grafting is a reliable and final surgical method for the repair of corneal perforation due to pterygium surgery. (*Turk J Ophthalmol* 2011; 41: 423-25)

Key Words: Complication, corneal grafting, mitomycin C, perforation, pterygium

Özet

Primer konjonktiva kapatması ve intraoperatif Mitomisin C kullanılarak yapılan pterijyum cerrahisi sonrası kornea perforasyonu oluşan üç olguyu ve korneal greftleme ile tedavi yaklaşımımızı sunmak. Dış merkezlerde primer konjonktiva kapatılması ve intraoperatif Mitomisin C yöntemi ile pterijyum cerrahisi uygulanan üç hasta, kornea perforasyonu nedeniyle kliniğimize refere edildi. Tüm olgularda nazal kornea bölgesinde lokalize perforasyon izlenmekteydi. Perforasyonların onarımı için korneal greftleme uygulandı. Greftleme tüm olgularda başarı sağladı, ve herhangi bir komplikasyon veya ek tedavi gereksinimi oluşmadı. Kornea perforasyonu pterijyum cerrahisinin nadir bir komplikasyonudur. Tektonik korneal greft uygulanması, pterijyum cerrahisine bağlı kornea perforasyonlarında güvenilir ve son basamak tedavi yöntemidir. (*Turk J Ophthalmol* 2011; 41: 423-25)

Anahtar Kelimeler: Komplikasyon, korneal greftleme, mitomisin C, perforasyon, pterijyum

Introduction

Although controversial, various pterygium surgery techniques have been described.¹⁻³ Primary conjunctival closure combined with intraoperative mitomycin C (MMC) application is a common procedure for both primary and especially for recurrent pterygium.¹⁻³ The use of MMC to prevent recurrence after pterygium surgery has increased considerably. Later on, a single intraoperative application is recommended due to late, sight-threatening complications of postoperative MMC drop instillation.⁴⁻⁶ However, intraoperative administration of MMC has been reported to be associated with delayed (more than 1

week) conjunctival wound healing.^{6,7} This delay is accused of predisposing to postoperative Dellen formation, infections, endophthalmitis, as well as scleral and corneal perforations.^{8,9}

Herein, we report three cases of corneal perforation after pterygium excision with primary conjunctival closure combined with intraoperative application of a single dose of 0.02% MMC, all of which were successfully treated with corneal grafting.

Case Reports

Case 1: A 63-year-old woman was referred to our clinic for corneal perforation in her right eye. The patient has undergone

Address for Correspondence/Yazışma Adresi: Dr. Melis Palamar Onay, Department of Ophthalmology, Ege University Faculty of Medicine, Izmir, Turkey

Phone.: +90 232 390 37 88 Gsm: +90 530 408 50 51 E-mail: osarac2002@yahoo.com

Received/Geliş Tarihi: 31.01.2011 **Accepted/Kabul Tarihi:** 17.05.2011

an uneventful pterygium surgery with primary conjunctival closure combined with 0.02% MMC, three months earlier elsewhere. During the first postoperative two months, no known complications were noted. However, on the postoperative third month, the patient started to feel irritation, itchiness, and pain. At the first admission to our clinic, visual acuity was 10/200 in the operated eye, and slit-lamp examination showed nasal corneal perforation which the referring doctor had tried to treat with conjunctival graft (Figure 1A). Slit-lamp examination revealed an inflamed conjunctival patch that was insufficient to stop the leakage, causing narrow anterior chamber and hypotony. No signs of infection were present, and microbiological analysis was negative. Her ocular and medical histories were otherwise unremarkable.

Case 2: A 50-year-old woman, who had undergone an uneventful pterygium surgery with primary conjunctival closure combined with 0.02% MMC elsewhere two months earlier, was referred to our clinic for corneal perforation in her left eye. Visual acuity was 8/20 in the operated eye, and slit-lamp examination showed nasal corneal perforation with iris prolapsus (Figure 2A). A shallow anterior chamber was present with no signs of infection. Microbiological analysis was negative. Her ocular and medical histories were otherwise normal. Remaining ocular examination was unremarkable.

Case 3: A 46-year-old man, who had undergone an uneventful pterygium surgery with 0.02% MMC elsewhere four months earlier, was referred to our clinic for corneal perforation in his left eye. Slit-lamp examination revealed corneal perforation at the nasal side with iris prolapsus and accompanying necrotizing scleritis (Figure 3A). Visual acuity in the operated eye was 10/200. The anterior chamber was shallow with no signs of infection. Microbiological analysis was negative. His ocular and medical histories were otherwise unremarkable.

Treatment Modality

All patients underwent full thickness corneal grafting for corneal perforation. For Cases 1 and 2, corneal buttons were obtained from two serologically suitable patients for organ donation, who underwent penetrating keratoplasty for keratoconus. The thicker peripheral part of the keratoconic buttons were reshaped according to defect size. In Case 3, corneal defect was repaired with the rim of a corneoscleral button, and a transpositional rotating conjunctival flap from the superomedial healthy conjunctiva was utilized for the closure of necrotizing

scleritis area. Corneal tissue was sutured to the surrounding cornea with 10/0 monofilament nylon sutures, and 8/0 vicryl sutures were used for conjunctival fixation.

After surgery, topical dexamethasone 0.1% (4 times daily), tobramycin 0.3% (4 times daily), and artificial tears 6 times per day were administered for one month.

Results

After corneal grafting together with topical steroid, antibiotic and artificial tear treatment, we observed rapid healing. In a week, the grafts were clear with no signs of

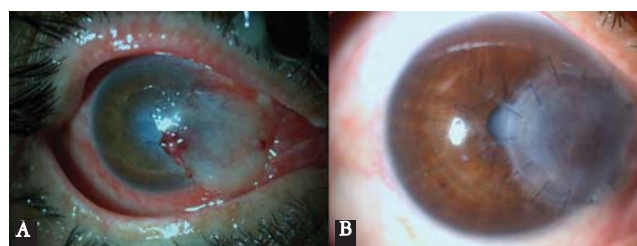


Figure 1. **A)** The inflamed conjunctival patch, inserted by the referring doctor to stop the leak is observed over the corneal perforation area. **B)** The corneal graft is visible, and the cataract formation is evident at postoperative 6 months

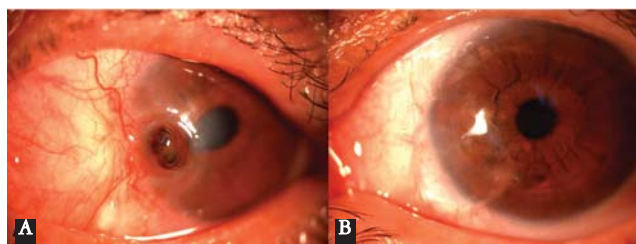

Figure 2. **A)** Corneal perforation and iris prolapsus is observed. **B)** The clear corneal graft is visible at postoperative 6 months

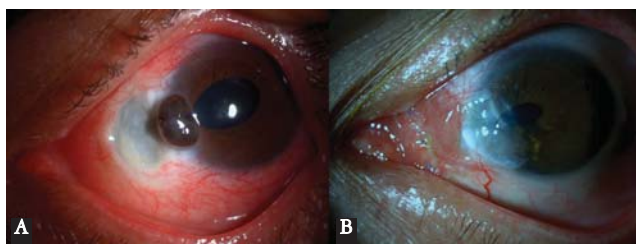


Figure 3. **A)** Corneal perforation and necrotizing scleritis area at the nasal side are evident. **B)** Corneal grafting and conjunctival flap are healthy with no signs of complication

Table 1. Demographics of the cases

Case	Sex	Age	Size of perforation (mm x mm)	Preoperative VA	Postoperative VA (3 months)	Keratometric astigmatism (3 months)
1	F	63	4,0x5,0	10/200	6/20	- 4,00x180
2	F	50	1,5x2,0	8/20	14/20	- 1,50x180
3	M	46	2,0 x2,5	10/200	18/20	- 3,50x80

infection. Over one month, the grafts were healthy in all cases with no wound leak (Figure 1B, Figure 2B, Figure 3B). All the eyes had a best-corrected visual acuity of 6/20 or better at the postoperative 6 month (Table). The keratometric astigmatism values after corneal grafting surgery were tolerable in all cases. In Case 1, there was cataract formation due to inflammation and topical corticosteroids. After cataract surgery the vision increased to 16/20.

Discussion

Although there are numerous newly developed techniques available for pterygium excision, recurrence remains a major concern.¹⁻³ To prevent recurrence, adjunctive therapies - some of which, such as MMC, topical cyclosporin A, beta irradiation, can be dangerous - are performed.^{1-3,10,11}

MMC is an alkylating agent that inhibits DNA synthesis, resulting in long-term inhibition of Tenon's fibroblast proliferation and prolonged wound healing.³⁻⁵ Although MMC helps to reduce recurrence, it brings the risk of potential serious complications, such as scleral necrosis, infectious scleritis, secondary glaucoma, iritis, corneal edema and corneal perforation.^{3-5,9} These complications have been reported in up to 13% of patients, with latency periods of up to 19 years, suggesting that patients may have a life-long risk of potentially blinding complications.^{3-5,9} There are various recommended types of application for MMC in pterygium surgery, such as subconjunctival injection, topical eyedrops, or intraoperative single dose application.^{4-6,12,13} The most secure type of MMC administration in pterygium surgery is a single intraoperative application.⁴⁻⁶

The reported interval between the occurrence of scleral melting and pterygium excision with MMC varies from postoperative 8 days to 5 to 12 years.^{9,13,14} Corneal perforations, all of which were located at the side of the previous pterygium head in all our cases, occurred three months after the operation. The MMC application together with probable excessive cautery use led to prolonged inhibition of wound healing causing necrotizing scleritis and corneal melting. The absence of any microorganisms and connective tissue or immunologic diseases supported our diagnosis.

Alternative methods, effective in appropriately selected patients for corneal perforation repair, include cyanoacrylate tissue adhesives, conjunctival flaps, amniotic membrane, autogenous grafts, and lamellar grafts.¹⁴⁻¹⁶ If available, tectonic corneal grafting is an excellent technique for ocular surface reconstruction, especially in large perforations as in our cases. Corneal tissue shortage is a major problem in many countries, and there are growing lists of keratoplasty candidates. As in our cases, one can consider to use the excised buttons from corneal dystrophy and ectasia patients for tectonic keratoplasty. After

corneal grafting and topical steroid, antibiotic and artificial tear treatment, we observed rapid healing. In a week, the grafts were clear and there were no signs of infection.

To the best of our knowledge, this is the first case series of corneal perforation secondary to pterygium excision with intraoperative MMC being successfully treated with corneal grafting.

The patient should be informed that the use of MMC intraoperatively may cause potential pain, corneal changes, and even more dangerous complications, such as scleral or corneal necrosis. Although rare, if corneal perforation develops, the defect can be covered with a corneal graft to successfully treat this sight-threatening complication.

References

- Hirst LW. The treatment of pterygium. *Surv Ophthalmol.* 2003;48:145-80.
- Fernandes M, Sangwan VS, Bansal AK, et al. Outcome of pterygium surgery: analysis over 14 years. *Eye (Lond).* 2005;19:1182-90.
- Nabawi KS, Ghonim MA, Ali MH. Evaluation of limbal conjunctival autograft and low dose mitomycin C in the treatment of recurrent pterygium. *Ophthalmic Surg Lasers Imaging* 2003;34:193-6.
- Rubinfeld RS, Pfister RR, Stein RM, et al. Serious complications of topical mitomycin C after pterygium surgery. *Ophthalmology.* 1992;99:1647-54.
- Saifuddin S, el Zawawi A. Scleral changes due to mitomycin C after pterygium excision. A report of two cases. *Indian J Ophthalmol.* 1995;43:75-6.
- Cardillo JA, Alves MR, Ambrosio LE, Poterio MB, Jose NK. Single intraoperative application versus postoperative mitomycin C eye drops in pterygium surgery. *Ophthalmology.* 1995;102:194-52.
- Panda A, Das GK, Tuli SW, Kumar A. Randomized trial of intraoperative mitomycin C in surgery for pterygium. *Am J Ophthalmol.* 1998;125:59-63.
- Cano-Parra J, Diaz LM, Maldonado MJ, Vila E, Menezes JL. Prospective trial of intraoperative mitomycin C in the treatment of primary pterygium. *Br J Ophthalmol.* 1995;69:439-41.
- Tsai YY, Lin JM, Shy JD. Acute scleral thinning after pterygium excision with intraoperative Mitomycin C. *Cornea.* 2002;21:227-9.
- Ibáñez M, Eugarríos MF, Calderón DI. Topical cyclosporin A and mitomycin C injection as adjunctive therapy for prevention of primary pterygium recurrence. *Ophthalmic Surg Lasers Imaging* 2009;40:239-44.
- Ali AM, Thariat J, Bensadoun RJ, et al. The role of radiotherapy in the treatment of pterygium: A review of the literature including more than 6000 treated lesions. *Cancer Radiother.* 2011;15:140-7.
- Khakshoor H, Razavi ME, Daneshvar R, Shakeri MT, Ghate MF, Ghooshkhanehi H. Preoperative subpterygeal injection vs intraoperative mitomycin C for pterygium removal: comparison of results and complications. *Am J Ophthalmol* 2010;150:193-8.
- Ti SE, Tan DT. Tectonic lamellar grafting for severe scleral melting after pterygium surgery. *Ophthalmology.* 2003;110:1126-36.
- Karalezli A, Kucukerdonmez C, Borazan M, Akova YA. Successful treatment of necrotizing scleritis after conjunctival autografting for 67
- Kim HK, Park HS. Fibrin glue-assisted augmented amniotic membrane transplantation for the treatment of large noninfectious corneal perforations. *Cornea.* 2009;28:170-6.
- Kremer I, Ehrenberg M, Weinberger D. Fresh-tissue corneolimbal covering graft for large corneal perforation following childhood trachoma. *Ophthalmic Surg Lasers Imaging.* 2009;40:245-50.
- Goto S, Fukuhara A, Miyasaka H. Therapeutic keratoplasty using preserved corneas from keratoconus eyes. *Jpn J Ophthalmol* 1999;43:517-21.