

Endothelial Line Associated with Keratic Precipitates in a Case of Herpetic Keratouveitis

Herpetik Keratoüveitli Vakada Keratik Presipitatlarla İlişkili Endotelyal Çizgi

Necip Kara

Kanuni Sultan Suleyman Education and Research Hospital, Department of Ophthalmology, İstanbul, Turkey

Summary

A 60-year-old male patient presented with decreased visual acuity, photophobia and redness in the left eye. Slit-lamp examination revealed diffuse large mutton-fat keratic precipitates (KPs) and a line which was parallel to the limbus in the peripheral corneal endothelium developed from KPs. A diagnosis of herpetic keratouveitis was made by clinical examination and laboratory work up. The patient was treated with systemic acyclovir, topical acyclovir, and topical steroid. The findings were resolved with therapy. (*Turk J Ophthalmol* 2012; 42: 241-2)

Key Words: Herpes simplex, keratouveitis, keratic precipitates

Özet

Altmış yaşında erkek hasta görme keskinliğinde azalma, fotofobi ve göz kızarıklığı ile başvurdu. Biyomikroskopik muayenede yaygın geniş mutton-fat keratik presipitatlara (KPs) ve periferik endotelde KPs'den oluşan limbusa paralel çizgi görüldü. Klinik muayene ve laboratuvar çalışmaları sonucunda herpetik keratoüveit tanısı kondu. Hasta sistemik asiklovir, topikal asiklovir ve topikal steroid ile tedavi edildi. Bulgular tedavi ile düzeldi. (*Turk J Ophthalmol* 2012; 42: 241-2)

Anahtar Kelimeler: Herpes simpleks, keratoüveit, keratik presipitat

Introduction

Ocular herpes simplex virus (HSV) infection may involve the anterior and posterior parts of the eye and results in various clinical disorders including blepharconjunctivitis, scleritis, episcleritis, keratitis, anterior uveitis, and posterior uveitis.¹⁻⁴ Herpes simplex virus (HSV) is one of the most common infectious causes of uveitis. HSV uveitis may present as keratouveitis, endothelitis, trabeculitis or a combination of these.⁵

Herein, we present the case of a patient with unilateral HSV keratouveitis in which a linear pattern of keratic precipitates (KPs) developed in the corneal endothelium.

Case report

A sixty-year-old male patient presented to our hospital complaining of decreased visual acuity, redness, and ocular

discomfort in his left eye over the previous month's time. His best corrected visual acuity was 20/100 in the right eye (OD) and hand motion in the left eye (OS).

Slit-lamp biomicroscopy revealed a ciliary injection, epithelial and stromal edema, diffuse mutton-fat KPs, posterior iris synechiae, and a corneal epithelial defect in the left eye. Also, a thick and semi-circular line, which was developed from the KPs, was seen at corneal endothelium as parallel to the limbus and extending from 5 to 9 o'clock positions (Figure 1). The intraocular pressure (IOP) was 32 mmHg in the left eye. The right eye had a significant nuclear cataract and was otherwise fully normal. Based on the clinical finding, a herpetic infection was suspected. The subsequent laboratory work up yielded a positive result for HSV type I.

The patient was treated with 400 mg of oral acyclovir 5 times daily, topical 3% acyclovir eye ointment 5 times daily, a topical steroid 6 times a day, and a topical beta-blocker as anti-glaucomatous therapy. After 3 days of medication administration,

Address for Correspondence/Yazışma Adresi: Dr. Necip Kara, Kanuni Sultan Suleyman Education and Research Hospital, Department of Ophthalmology, Turkey Phone.: +90 212 251 59 00 E-posta: dr.necipkara@gmail.com

Received/Geliş Tarihi: 23.09.2011 **Accepted/Kabul Tarihi:** 16.11.2011

the KPs reduced and became a small, endothelial line that was disrupted, and the epithelial defect improved (Figure 2). The IOP was 16 mmHg in the left eye. After 7 days of medication administration, the endothelial line had thinned and the KPs continued to reduce in size. The corneal edema also diminished. After 2 weeks of medication administration, the visual acuity in the left eye had improved to 20/200. The KPs had reduced and the endothelial line was nebulous (Figure 3). Also, the left eye had

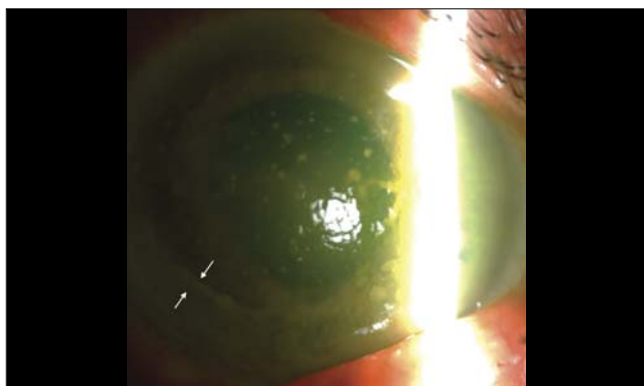


Figure 1. Slit-lamp examination of the left eye showing an endothelial line (i.e., highlighted by the arrow), KPs, and corneal edema at the beginning




Figure 2. Appearance of the cornea after 3 days of treatment with medication. The endothelial line is disrupted (i.e., highlighted by the arrow); the KPs have reduced, and the corneal edema has diminished

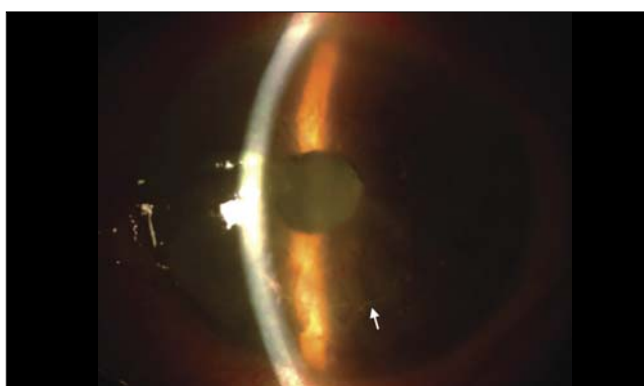


Figure 3. After 2 weeks of treatment with medication, the endothelial line (i.e., highlighted by the arrow) is nebulous

a nuclear cataract that contributed to the reduced visual acuity. Subsequent follow-up could not be completed due to journey of the patient to another city.

Discussion

HSV is one of the most common infectious causes of uveitis; i.e., it accounts for up to 9% of cases of anterior uveitis in published studies.^{6,7} Herpetic uveitis is frequently accompanied by corneal involvement, thereby causing keratitis. The clinical features of an anterior herpetic uveitis may include corneal scarring, decreased corneal sensation, iris atrophy, anterior and/or vitreous cells, granulomatous or non-granulomatous KPs, posterior synechiae, and elevated IOP.^{8,9}

In this case, we observed a visible line on the endothelium caused by linear accumulations of endothelial KPs similar to the Khodadoust line seen with corneal graft rejection. To our knowledge, this is the thickest endothelial line associated with HSV keratouveitis. In this case, this endothelial line was indeed thicker as compared to the previously reported endothelial lines. This may be explained by the greater dimension of KPs in our case. Further studies using specular microscopy or anterior segment optical coherence tomography images may be helpful in terms of demonstration of an endothelial line composed by KPs. With medical therapy, the endothelial line was thinned to the point at which it was barely visible.

In summary, herpetic keratouveitis may cause a linear pattern of KPs in the corneal endothelium. Also, disappearance or reduction of this endothelial line may be considered as a response to treatment.

References

1. Perry HD, Doshi SJ, Donnenfeld ED, Levinson DH, Cameron CD. Herpes simplex reactivation following laser in situ keratomileusis and subsequent corneal perforation. *CLAO J.* 2002;28:69-71.
2. PePOSE JS, Laycock KA, Miller JK, et al. Reactivation of latent herpes simplex virus by excimer laser photokeratectomy. *Am J Ophthalmol.* 1992;114:45-50.
3. Vrabec MP, Anderson JA, Rock ME, et al. Electron microscopic findings in a cornea with recurrence of herpes simplex keratitis after excimer laser phototherapeutic keratectomy. *CLAO J.* 1994;20:41-4.
4. Cingü AK, Şahin A, Şahin M, Çinar Y, Ari Ş, Çaça İ. Tekrarlayan Herpetik Keratoüveit ve Sklerit Birlikteği; Nadir Bir Olgu Sunumu. *Glokom-Katarakt.* 2011;6:132-4.
5. Fong Choong Y, Austin MW. Secondary glaucoma associated with anterior uveitis, iris pigment epithelitis and herpetic eye infection. *Acta Ophthalmol Scand.* 2002;80:672-4.
6. Dhaliwal DK, Romanowski EG, Yates KA, Hu D, Goldstein M, Gordon YJ. Experimental laser-assisted in situ keratomileusis induces the reactivation of latent herpes simplex virus. *Am J Ophthalmol.* 2001;131:506-7.
7. Dhaliwal DK, Romanowski EG, Yates KA, et al. Valacyclovir inhibition of recovery of ocular herpes simplex virus type 1 after experimental reactivation by laser in situ keratomileusis. *J Cataract Refract Surg.* 2001;27:1288-93.
8. Preciado-Delgado Mdel C, Lorenzo-Mejia A, Hitos-Fajer A, Arellanes-García L. Herpetic keratouveitis in children. *Int Ophthalmol Clin.* 2008;48:39-49.
9. Aksoy S, Akova YA. Herpetik önüveitlerde klinik tanı ve tedavi- orjinal araştırma. *Turk J Ophthalmol.* 2009;39:485-90.