



Total Improvement of Ophthalmic Findings with Treatment in a Case with Iatrogenic Carotid-Cavernous Fistula

Iatrojenik Karotikokavernöz Fistül Olgusunda Tedavi ile Oküler Bulgularda Tam Düzelmeye

Ebru Nevin Çetin, Gülden Saraç, İlkay Sitti*, Avni Murat Avunduk, İsmail Oran**, Bayram Çırak*

Pamukkale University Faculty of Medicine, Department of Ophthalmology, Denizli, Turkey

*Pamukkale University Faculty of Medicine, Department of Neurosurgery, Denizli, Turkey

**Ege University Department of Radiology, Izmir, Turkey

Summary

A 45-year-old male presented with lid edema and blurred vision in his left eye. He had a history of operation for a sellar and parasellar mass 1 month ago. Best-corrected visual acuity was 7/10 in his left eye. He had marked lid edema, prominent chemosis, episcleral vascular injection, proptosis and mildly congested and tortuous retinal vessels in the left eye. Intraocular pressure was 35mmHg and eye movements were severely restricted in all directions in his left eye. Orbital magnetic resonance (MR) imaging showed left proptosis and cranial venous MR angiography demonstrated multiple tortuous and enlarged vessels near the left carotid artery and the left cavernous sinus resembling carotid-cavernous fistula, and enlarged superior ophthalmic vein. The patient underwent successful endovascular stent-graft implantation for the left iatrogenic carotid-cavernous fistula. At postoperative 3 weeks, visual acuity was 10/10 with complete regression of proptosis and restriction in his left eye. (*Turk J Ophthalmol 2012; 42: 393-6*)

Key Words: Carotid-cavernous fistula, exophthalmos, glaucoma, iatrogenic, ophthalmoplegia

Özet

Kırk beş yaşında erkek hasta, sol gözde kapak ödemi ve bulanık görme şikayeti ile başvurdu. Bir ay önce sellar ve parasellar kitle nedeniyle opere edilen hastanın görme keskinliği sol gözde 0.7 idi. Sol gözde ayrıca belirgin kapak ödemi, kemozis, episkleral vasküler injeksiyon, proptozis, retinal venlerde hafif konjesyon ve kıvrımlanma artışı saptandı. Göz içi basıncı 35mmHg ölçülen sol gözde, hareketlerin her yöne kısıtlı olduğu izlendi. Orbital manyetik rezonans (MR) görüntülemesinde sol proptozis; kraniyal venöz MR anjiyografide, karotikokavernöz fistül ile uyumlu olarak, sol karotid arter ve kavernöz sinus komşuluğunda vasküler yapıda kıvrımlanma artışı ve genişleme, ayrıca üst oftalmik vende genişleme saptandı. Sol iatrojenik karotikokavernöz fistül tanısıyla endovasküler greft-stent implantasyonu yapılan hastanın, işlem sonrası 3. haftada sol gözde görme keskinliğinin tam olduğu, proptozis ve göz hareketlerindeki kısıtlılığın ortadan kalktığı izlendi. (*Turk J Ophthalmol 2012; 42: 393-6*)

Anahtar Kelimeler: Eksoftalmus, glaukom, iatrojenik, karotikokavernöz fistül, oftalmopleji

Introduction

A carotid-cavernous fistula (CCF) is an abnormal communication between the carotid artery and the cavernous sinus, which is characterized by increased episcleral venous pressure and decreased arterial blood flow to the cranial nerves within the cavernous sinus. Trauma is responsible for 75% of the cases and spontaneous rupture of an intracavernous carotid artery aneurysm or an atherosclerotic artery are the reasons for the remainder.¹ Here we report a

case of iatrogenic CCF with improvement in ocular findings following endovascular stent-graft implantation.

Case Report

A 45-year-old male presented with lid edema and blurred vision in his left eye for 10 days. He had had an operation for a sellar and parasellar mass 1 month ago. Best-corrected visual acuity was 10/10 in his right eye and 7/10 in his left eye. He had unremarkable anterior and posterior segment

Address for Correspondence/Yazışma Adresi: Dr. Ebru Nevin Çetin, Pamukkale University Faculty of Medicine, Department of Ophthalmology, Denizli, Turkey
Phone: +90 242 444 07 28 Gsm: +90 525 16 27 E-mail: ecetin@pau.edu.tr

Received/Geliş Tarihi: 21.12.2011 **Accepted/Kabul Tarihi:** 06.02.2012

findings in his right eye. In his left eye, he had marked lid edema, minimal inferior corneal staining, prominent chemosis, episcleral vascular injection, and exophthalmos (Figure 1). Anterior chamber and lens were normal, retinal venous vessels were tortuous and mildly congested (Figure 2). Intraocular pressure was 11mmHg OD and 35 mmHg OS. On Hertel exophthalmometer, the measurement of the right eye was 20mm and of the left eye was 26 mm. Eye movements were severely restricted (-3) in all directions in his left eye. Visual field test was normal OU. Orbital magnetic resonance (MR) imaging showed left proptosis and cranial venous MR angiography demonstrated multiple tortuous and enlarged vessels near the left carotid artery and the left cavernous sinus resembling CCF, and enlarged superior ophthalmic vein (Figure 3, 4). Following IOP control with topical and systemic medication, he underwent successful endovascular stent-graft implantation for left iatrogenic CCF. At postoperative 3 weeks, exophthalmos and restriction in eye movements totally regressed and the visual acuity was 10/10 in his left eye (Figure 5).

Discussion

CCF can be categorized as traumatic/spontaneous, direct/indirect, or high/low flow fistulas. In direct fistula, there is a shunt between the internal carotid artery and the cavernous sinus,

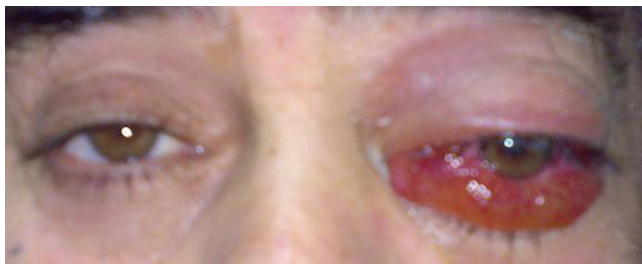

Figure 1. Marked exophthalmos, lid edema, prominent chemosis, episcleral vascular injection and ophthalmoplegia in the left eye

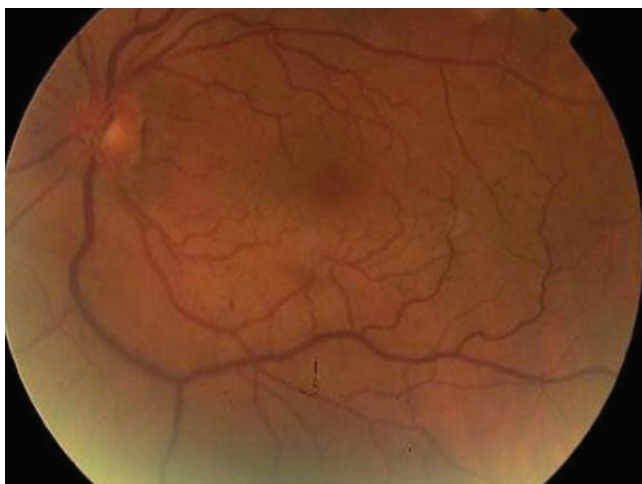


Figure 2a. Tortuosity and mild congestion in the retinal veins at presentation

whereas in indirect fistula, the intracavernous portion of the internal carotid artery remains intact and arterial blood flows through the meningeal branches of the carotid artery into the cavernous sinus. 1 A high flow fistula is mostly a direct fistula with rapidly developing ocular signs as in our case and a low flow fistula is an indirect fistula with more subtle clinical features which can easily be misdiagnosed.

Iatrogenic CCF occurs as iatrogenic ICA injury creates a communicating channel between the cavernous sinus and the ICA. Iatrogenic CCF was previously reported after sphenoid sinus biopsy, transsphenoidal surgery for pituitary adenoma, nasal septoplasty and carotid endarterectomy with Fogarty catheter.²⁻⁵

In CCF, diversion of arterialized blood into the venous system causes elevation of episcleral venous pressure and ischemic ocular damage.⁶ The common ocular features of CCF are ptosis, exophthalmos, red and chemotic conjunctiva, tortuous epibulbar vessels and raised intraocular pressure

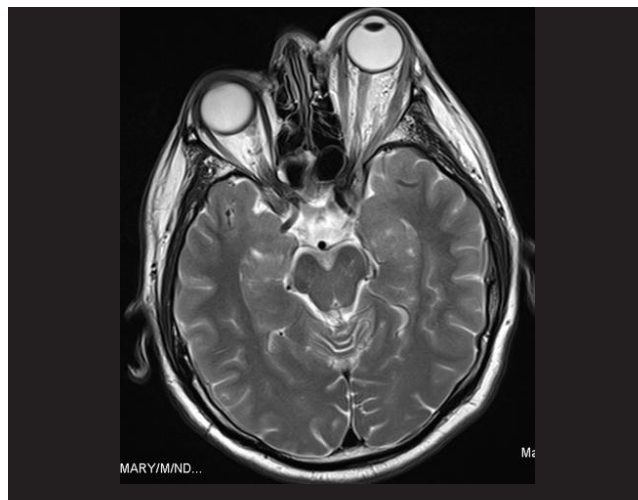

Figure 3. Axial cranial MR imaging showing left-sided proptosis

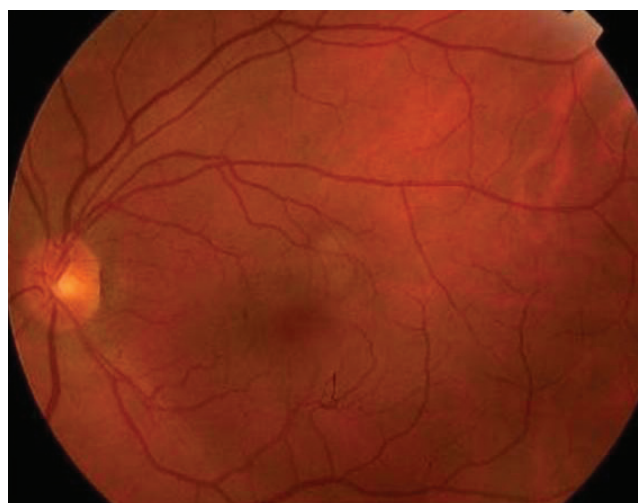


Figure 2b. Regression of tortuosity and congestion in the retinal veins after treatment in the left eye

secondary to increased episcleral venous pressure. Exophthalmos might be pulsating type in direct CCF. Anterior segment necrosis occurs in 20% of the patients, which is characterized by corneal edema, iritis, iris atrophy, rubeosis and cataract. Fundus findings may show venous engorgement, tortuosity, choroidal folds and occasionally central retinal vein occlusion.^{1,6} Increased pressure in the cavernous sinus can cause compression of cranial nerves (most commonly IV) and ophthalmoplegia.⁶ Engorgement and enlargement of extraocular muscles may further interfere ocular motility. 1 Clinical features may show variety according to the flow power, the level of intraocular pressure and duration of the condition. Our case demonstrated typical features of direct CCF including exophthalmos, glaucoma, red and chemotic conjunctiva and ophthalmoplegia.

Secondary glaucoma, diplopia, headache, and severe proptosis are the main indications for treatment of CCF.¹ Traumatic fistulae are much less likely to close spontaneously because of their high flow. Embolization of the fistula through endovascular transarterial or transvenous route is generally successful in CCF. Therapeutic endovascular techniques for ICA occlusion are simple, and they can be performed immediately after the diagnostic angiographic study.² Transluminal endovascular placement of stent-grafts for the treatment of head and neck aneurysms and direct arteriovenous fistulae was reported to be successful in selected patients.^{5,7} Yet, some patients are still candidates for surgical bypass because of the failure of endovascular treatment.

Regarding iatrogenic CCF, there is limited data about the visual prognosis following treatment. In our case, CCF was successfully closed, visual acuity increased to 10/10,

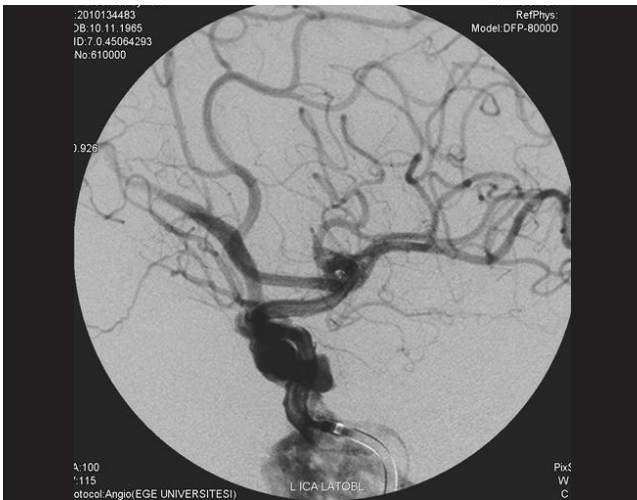


Figure 4a. Left carotid angiography, left oblique projection, demonstrates the left cavernous sinus and the left superior ophthalmic vein opacification due to the carotid-cavernous fistula

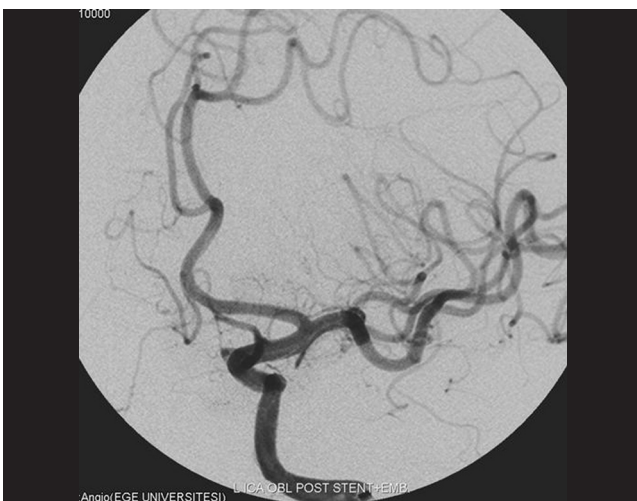

Figure 4b. Left carotid angiography, left oblique projection, reveals disappearance of the fistula with normal arterial tree after treatment

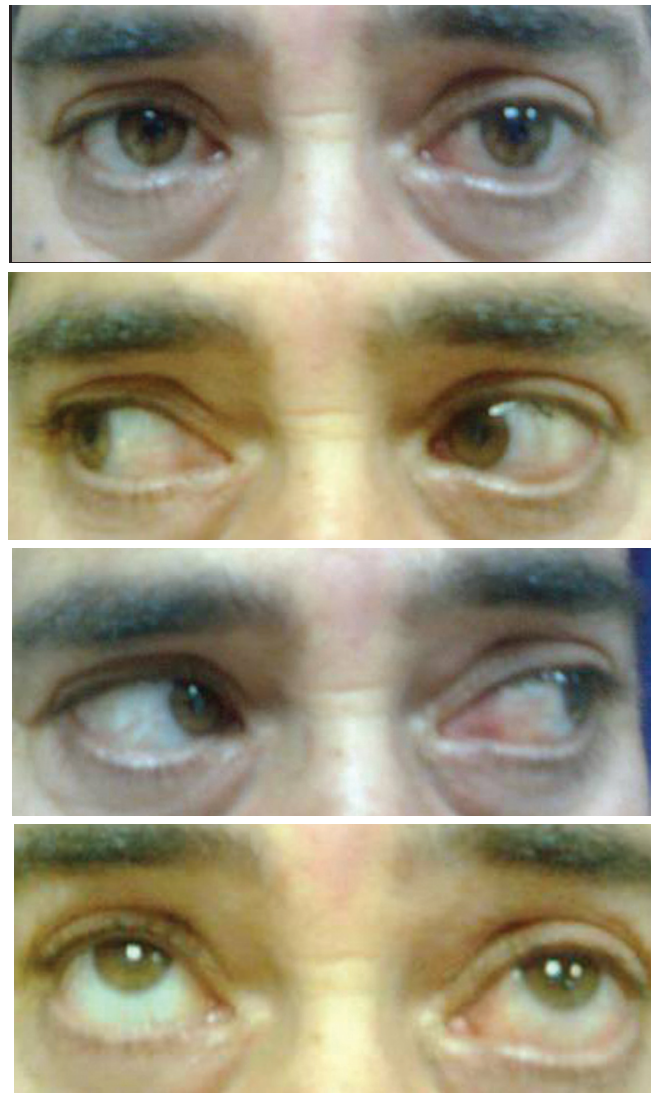

Figure 5. Improvement in the ocular findings and restriction of eye movements after treatment

exophthalmos regressed, and all ocular findings returned to normal after treatment within 3 weeks. However, especially in direct traumatic fistula, visual impairment may be permanent and unresponsive to treatment.⁸ Gupta et al.⁹ reported visual deficit in 25% of the CCF patients with complete recovery. In a recent report, seven of the nine patients with reduced vision secondary to direct CCF, had complete or nearly complete restoration of vision after endovascular interventional treatment. The remaining two patients who had no recovery of vision after treatment, had presented with nil perception of light and one of them was diagnosed with a delay of 6 weeks. The number of cases with a missed diagnosis either during the first admission or at the first specialist consultation was 3 out of 12 in the direct CCF group and 7 out of 12 in the indirect CCF group.¹⁰

In conclusion, although most of the cases are traumatic, CCF can occur secondary to surgeries and may have favorable prognosis unless diagnosed late. The recovery of vision seems to be more likely in the early diagnosed cases. Therefore, history of surgery should also be questioned in patients presenting with a decreased vision, red and exophthalmic eye with ophthalmoplegia.

References

1. Kanski J. Orbit. In: Jack J Kanski ed. Clinical Ophthalmology (6th edition). Philadelphia; Butterworth Heinemann; 2007:165-203.
2. Kocer N, Kizilkilic O, Albayram S, Adaletli I, Kantarci F, Islak C. Treatment of iatrogenic internal carotid artery laceration and carotid cavernous fistula with endovascular stent-graft placement. *AJNR Am J Neuroradiol.* 2002;23:442-6.
3. Dolenc VV, Lipovsek M, Slokan S. Traumatic aneurysm and carotid-cavernous fistula following transsphenoidal approach to a pituitary adenoma: treatment by transcranial operation. *Br J Neurosurg.* 1999;13:185-8.
4. Moin H, Mohagheghzadeh O. Carotid Cavernous Fistula Subsequent to Nasal Septoplasty; A Case Report. *Journal of Research in Medical Sciences.* 2005;10:112-3.
5. Felber S, Henkes H, Weber W, Miloslavski E, Brew S, Kühne D. Treatment of extracranial and intracranial aneurysms and arteriovenous fistulae using stent grafts. *Neurosurgery.* 2004;55:631-8.
6. No Authors Listed. Orbital neoplasms. In: *Orbits, eyelids and lacrimal system.* San Francisco; American Academy of Ophthalmology;2010:68-69.
7. Oran I, Bozkaya H, Parildar M. Embolisation of both fistulae through the same carotid artery tear in a patient with bilateral traumatic caroticocavernous fistulae. *Neuroradiology.* 2004;46:234-7.
8. de Keizer R. Carotid-cavernous and orbital arteriovenous fistulas: ocular features, diagnostic and hemodynamic considerations in relation to visual impairment and morbidity. *Orbit.* 2003;22:121-42.
9. Gupta AK, Purkayastha S, Krishnamoorthy T et al. Endovascular treatment of direct carotid cavernous fistulae: a pictorial review. *Neuroradiology.* 2006;48:831-9.
10. Barry RC, Wilkinson M, Ahmed RM et al. Interventional treatment of carotid cavernous fistula. *J Clin Neurosci.* 2011;18:1072-9.