



Fakoemülsifikasyon Cerrahisinden 5 Yıl Sonra Yan Girişin Açılması ve İris Prolapsusu: Olgu Sunumu

Wound Dehiscence and Iris Prolapse Through Side-Port Incision 5 Years After Phacoemulsification Surgery: Case Report

Volkan Hürmeriç, Osman Melih Ceylan, Umut Karaca, Fazıl Cüneyt Erdurman

Gulhane Military Medical Faculty Department of Ophthalmology, Ankara, Turkey

Summary

A 65-year-old man was referred to our institution for the evaluation of redness in the right eye. The patient sustained a blunt trauma 10 days previously and had a history of bilateral uncomplicated phacoemulsification performed 5 years earlier. His examination revealed iris prolapse through the side-port incision in the right eye. The patient underwent wound and iris repair. Our case report demonstrates that small sized clear corneal incisions used in cataract surgery have a risk for development of late traumatic wound dehiscence. To the best of our knowledge, late iris prolapse from a side-port incision have not been reported before. We believe that advanced corneal incision configurations with femtosecond laser systems may decrease the risk of similar complications in the future. (*Turk J Ophthalmol* 2013; 43: 55-6)

Key Words: Wound dehiscence, iris prolapse, phacoemulsification

Özet

65 yaşında erkek hasta sağ gözündeki kızarıklık nedeniyle kliniğimize başvurdu. Hasta 10 gün önce gözüne künt travmaya maruz kalmıştı ve 5 yıl önce her iki gözünden fakoemülsifikasyon cerrahisi geçirmişti. Yapılan muayenede sağ gözde daha önceki ameliyatta hazırlanan yan kesiden iris prolapsusu olduğu gözlemlendi. Hastaya acil olarak kesi ve iris tamiri uygulandı. Sunduğumuz olgu katarakt cerrahisinde kullanılan küçük kesi kornea insizyonlarının, hatta yan kesilerin bile geç dönemde travma ile açılabileceğini göstermektedir. Yaptığımız araştırmaya göre ameliyattan sonra geç dönemde yan kesiden iris prolapsusu daha önce bildirilmemişti. İleride kullanıma girecek olan femtosaniye katarakt sistemleri ile yapılabilen alternatif kornea kesi şekillerinin bu tip komplikasyonların oluşma riskini azaltacağına inanıyoruz. (*Turk J Ophthalmol* 2013; 43: 55-6)

Anahtar Kelimeler: Yara ayrılması, iris prolapsusu, fakoemülsifikasyon

Introduction

Current trend in cataract surgery is to minimize the size of incisions used during phacoemulsification. It is known that small sized incisions allows rapid visual rehabilitation, produce less astigmatic effect, reduce postoperative wound leak, and decrease the risk of endophthalmitis.¹ Although small sized incision increases the stability of the surgical wound, traumatic wound dehiscence after blunt trauma has been reported after phacoemulsification.^{2,3} In this paper, we report a patient with traumatic iris prolapse through the side-port incision which developed 5 years after phacoemulsification surgery. To the best of our knowledge, dehiscence of a side-port incision in cataract surgery has not been reported previously.

Case

A 65-year-old man was referred to our institution for the evaluation of redness in the right eye. His eye was struck with his granddaughter's finger 10 days previously and the patient had used topical antibiotics since then. His initial ophthalmologic examination revealed iris prolapse through the nasal side and corrected distance visual acuity (CDVA) of 20/40 in the right eye (Figure 1a).

His medical records revealed that he had bilateral phacoemulsification surgery performed in our institution 5 years earlier. The right eye was operated through a 3.2 mm clear corneal incision at the 11 o'clock position. Two side-port incisions were made with a microvitrectomy blade and the

Address for Correspondence/Yazışma Adresi: Dr. Volkan Hürmeriç, Gulhane Military Medical Faculty Department of Ophthalmology, Ankara, Turkey

Phone: +90 312 304 58 73 E-mail: drvolki@yahoo.com **Received/Geliş Tarihi:** 18.12.2011 **Accepted/Kabul Tarihi:** 15.05.2012

nasal incision was enlarged manually during the surgery. A 3-piece, 18.5 diopter intraocular lens (IOL) (AMO Sensar AR40e, Illinois, USA) was implanted after uneventful phacoemulsification.

The patient underwent emergency wound repair. We preferred to excise the prolapsed iris tissue due to prolonged time between the blunt trauma and the surgical intervention. During the surgery, the width of the side-port incision with wound dehiscence was measured as 2 mm with a surgical caliper. We sutured the iris defect with two interrupted 10-0 prolene sutures and the side-port incision with two interrupted 10/0 nylon sutures. After surgery, antibiotic and steroid eye-drops were prescribed four times daily for 4 weeks. On the tenth postoperative day, the anterior chamber was deep and quiet. There was pupil retraction towards the side-port incision, and CDVA was 20/20 (Figure 1b). At the 2-month postoperative visit, slit lamp findings and CDVA were unchanged.

Discussion

Traumatic wound dehiscence is a well-known risk in cataract surgery. Previous reports addressed this problem more commonly in patients with extracapsular cataract extraction (ECCE). In a series with 848 open-globe injuries, 7.4% of cases presented with traumatic wound dehiscence after cataract surgery.¹ In these patients, only 11% of the cases underwent phacoemulsification. To the best of our knowledge, the longest time previously reported from surgery to wound dehiscence after phacoemulsification was 1 year.^{1,4,5,6} In our patient, wound dehiscence was observed 5 years after surgery. Besides, the dehiscence in our patient was from the side-port incision, which was not reported previously in the literature.

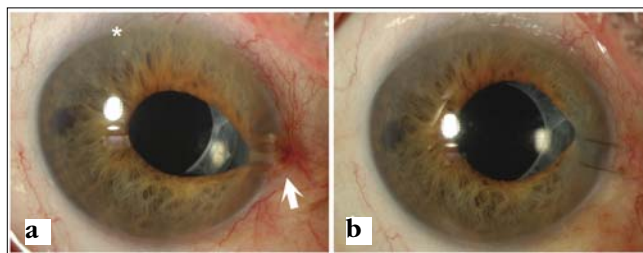


Figure 1. Slit lamp pictures of the patient. **a)** Preoperative slit lamp picture demonstrating iris prolapse (white arrow) through the nasal side-port incision. White asterisk demonstrates the location of the 3.2 mm clear corneal incision. **b)** Slit lamp photograph of the patient on the tenth postoperative day demonstrating pupil retraction and 2 interrupted 10/0 nylon sutures at the repaired side-port incision

It is known that the globe rupture develops at the weakest point of the globe after blunt trauma. Although the largest incision in our patient was the superior 3.2 mm entry, the wound dehiscence had developed from the side-port incision. We believe that inappropriate design of the corneal wound or manually enlarging of the incision may be responsible in the development of this complication in its unusual location. The direction of the trauma may also contribute to the development of this outcome.

Patient age is another risk factor in the development of wound dehiscence after cataract surgery. Kloek's study demonstrated that 90% of the patients with post-cataract surgery wound dehiscence were older than 65 years. Falls, motor vehicle accidents are the most common mechanisms of injuries reported in these patients.^{1,3,4,5} In most of the cases, multiple surgical procedures were required in the management of traumatic ocular damage. Our patient sustained a relatively minor blunt trauma and did not have an ophthalmic examination for 10 days. The prolapsed iris tissue probably sealed the side-port incision and prevented the development of a more serious complication such as endophthalmitis in our patient. However, the prolonged time between the trauma and surgical repair forced us to excise the prolapsed iris tissue. Although we have sutured the iris defect, significant pupil retraction was developed postoperatively. Earlier surgical intervention could have prevented the iris excision and may have resulted in a better outcome in our patient.

As a conclusion, our case demonstrates that the side-port incision used in cataract surgery have a risk to develop late traumatic wound dehiscence. We believe that new wound configurations available with femtosecond laser systems will enhance the wound strength of clear corneal incisions and decrease the risk of similar complications in the future.

References

1. Kloek CE, Andreoli MT, Andreoli CM. Characteristics of traumatic cataract wound dehiscence. *Am J Ophthalmol.* 2011;152:229-33.
2. Ernest PH, Lavery KT, Kiessling LA. Relative strength of scleral corneal and clear corneal incisions constructed in cadaver eyes. *J Cataract Refract Surg.* 1994;20:626-9.
3. Blomquist PH. Expulsion of an intraocular lens through a clear corneal wound. *J Cataract Refract Surg.* 2003;29:592-4.
4. Hurvitz LM. Late clear corneal wound failure after trivial trauma. *J Cataract Refract Surg.* 1999;25:283-4.
5. Routsis P, Garston B. Late traumatic wound dehiscence after phacoemulsification. *J Cataract Refract Surg.* 2000;26:1092-3.
6. Ball J, Caesar R, Choudhuri D. Mystery of the vanishing iris. *J Cataract Refract Surg.* 2002;28:180-1.