



Donor Cornea Use in Scleral Surface Reconstruction

© Ayşe Burcu, © Züleyha Yalnız-Akkaya, © Evin Şingar Özdemir, © Selma Özbek-Uzman

University of Health Sciences Turkey Ankara Training and Research Hospital, Ankara, Turkey

Abstract

Objectives: To investigate the indications for and results of treating scleral surface problems with donor corneal grafts that are not used in keratoplasty surgery or are left over from keratoplasty.

Materials and Methods: The records of 16 patients in whom corneal tissue was used to repair a scleral tissue defect or cover an exposed glaucoma drainage implant were evaluated retrospectively. Partial-thickness grafts were prepared using a combined microkeratome system with artificial anterior chamber in 10 eyes and by manual dissection in 3 eyes. Full-thickness grafts were used in 3 eyes.

Results: There were 8 female and 8 male patients aged 5-79 years (mean: 39.37 ± 24.68). Indications for the use of corneal tissue on the scleral surface were limbal dermoid excision (n=2), pterygium surgery (n=1), intraocular lens removal and scleral fixation intraocular lens (SFIOL) implantation (n=1), exposed SFIOL suture coverage (n=1), trauma (n=2), scleral tissue loss due to repeated glaucoma surgeries (n=5), and exposed glaucoma drainage implant (n=4). The patients were followed for 6-42 months (mean: 14.37 ± 9.14). None of the patients had graft infection, thinning, immunological graft rejection, or vision loss during follow-up. Tectonic lamellar grafts did not adversely affect final visual acuity in any case. At final examination, a good combination of graft and recipient tissue, a smooth ocular surface, and a cosmetic appearance were achieved in all eyes.

Conclusion: Donor corneas that are not suitable for corneal transplantation or left over from the cornea transplant can be used in patients with scleral tissue loss due to various pathologies and in the treatment of glaucoma drainage implant erosion. In these cases, the use of corneal grafts provides a good ocular surface restoration and cosmetic appearance. The effectiveness and safety of this method should be investigated with large patient series and long follow-up times.

Keywords: Lamellar patch graft, scleral tissue loss, glaucoma drainage surgery

Introduction

Scleral tissue defects may occur due to ocular traumas, infectious or autoimmune scleral diseases, the removal of congenital or acquired tumoral masses in or adjacent to the sclera, and other anterior segment surgeries such as glaucoma, pterygium, and cataract surgery. Scleral tissue defects that develop for various reasons pose a risk for endophthalmitis.¹ Depending on their size, they may be cosmetically unattractive, as well as compromise the tectonic integrity of the globe.² Surgical repair of scleral tissue defects is necessary for tectonic and

therapeutic purposes. The basic principle of surgical treatment is to restore the scleral defect with autologous or allogeneic grafts and prevent the development of infection. If infection is present, debridement of the infected tissue and additional anti-infective therapy are required.

Partial-thickness autologous sclera, Tenon, and conjunctival supports and numerous allogeneic patch graft materials are used to provide tectonic support to scleral defects.^{3,4,5,6} Partial-thickness autologous scleral tissue grafts may cause damage and tectonic weakness at the graft preparation site. In large scleral defects, Tenon's capsule and conjunctiva may not provide

Address for Correspondence: Ayşe Burcu, University of Health Sciences Turkey Ankara Training and Research Hospital, Ankara, Turkey

E-mail: anurozler@yahoo.com.tr **ORCID-ID:** orcid.org/0000-0002-2345-0456

Received: 21.07.2020 **Accepted:** 12.10.2020

Cite this article as: Burcu A, Yalnız-Akkaya Z, Şingar Özdemir E, Özbek-Uzman S. Donor Cornea Use in Scleral Surface Reconstruction. Turk J Ophthalmol 2021;51:192-198

sufficient tectonic support, necessitating the use of allogeneic patch grafts.

Glaucoma drainage implants may erode the overlying tissue and become exposed over time. It occurs in 5-10% of cases.^{7,8,9} Autologous conjunctivo-Tenonplasty is often inadequate, and the implant must be covered with allogeneic materials such as sclera, pericardium, dura mater, and donor cornea.

In this study, we present the indications and results of the use of donor corneal grafts that are not used in keratoplasty surgery or are left over from keratoplasty in the treatment of scleral surface problems.

Materials and Methods

The records of patients for whom donor cornea was used to treat scleral surface pathologies between May 2016 and June 2019 were analyzed retrospectively. The study was approved by the Clinical Research Ethics Committee of University of Health Sciences Turkey Ankara Training and Research Hospital (study e. kurul-E-20/307) and a preoperative informed consent form was obtained from each patient. Sixteen eyes of 8 female and 8 male patients were included in the study. The patients' demographic data, ophthalmic history, previous surgical procedures, systemic diseases, slit-lamp examination findings, operative details of corneal graft use, postoperative medications, initial and final visual acuity, complications, need for additional surgical treatment, follow-up time, and clinical outcomes were obtained from hospital records and surgical videos.

The operations were performed under local or general anesthesia by two surgeons (A.B. and Z.Y.A.). Depending on the size of the defect, the donor corneal margin remaining after keratoplasty surgery, the anterior stromal lamellae remaining after descemet stripping endothelial keratoplasty (DMEK), or seronegative donor corneas unsuitable for optical keratoplasty were used. As needed according to the depth of the defect, grafts were prepared at the desired thickness using a combined artificial anterior chamber and microkeratome system (ALTK System, Moria/Microtech Inc. Doylestown, PA, USA) or were prepared manually to partial thickness. The following were ensured during surgery:

- The graft epithelium was debrided in all cases.
- After the necrotic sclera was cleared, the size of the healthy scleral and choroidal bed was measured. Based on the size and depth of the defect, a full-thickness or lamellar graft approximately 0.5-1 mm larger than the area to be covered was prepared from the donor cornea.
- In the limbal region, care was taken to ensure that grafts were thick enough to avoid dellen formation and that the corneoscleral junction approximated a natural appearance.
- The graft was sutured to the scleral bed and limbal margins with 10/0 monofilament nylon sutures.
- In cases of glaucoma drainage implant exposure, care was taken to center the partial-thickness graft over the area of exposure and suture it in a watertight manner.

- In order to prevent postoperative graft melting and to ensure epithelialization, it was covered by freeing conjunctival and Tenon's tissue surrounding the donor corneal grafts or using amniotic membrane in cases where adequate Tenon-conjunctival flap could not be obtained.

Postoperatively, 1% prednisolone acetate was used at 2-hour intervals for the first week and then at a reduced dose for 3-6 months. Moxifloxacin 0.5% was administered 4-6 times a day for 2 weeks. Topical lubricants were used every 2-4 hours. Patients were followed up on day 1, 7, and 15, then once a month for the first 3 months, and every 3-6 months thereafter.

In the absence of loosening or vascularization, the sutures were removed at 9-12 months.

Results

The 8 female and 8 male patients were between 5 and 79 years of age (mean: 39.37 ± 24.68). Indications for the use of corneal tissue on the scleral surface were limbal dermoid excision (n=2) (Figure 1a), scleral melting after pterygium surgery (n=1), intraocular lens (IOL) removal and scleral fixation intraocular lens (SFIOL) implantation (n=1), exposed SFIOL suture coverage (n=1), trauma (n=2), scleral tissue loss due to repeated glaucoma surgeries (n=5) (Figure 2a), and exposed glaucoma drainage implant (n=4) (Figure 3a). The demographic and clinical features of the patients are presented in Table 1.

Donor corneal rim remaining from keratoplasty was used in 5 eyes, stroma left over from DMEK was used in 1 eye, and donor corneas unsuitable for optical keratoplasty were used in 10 eyes. Partial-thickness grafts were prepared by manual dissection for 3 eyes and using an artificial anterior chamber and microkeratome system for 10 eyes.

Corneal grafting on the scleral surface was performed during primary surgery in only one case (patient 1, limbal dermoid); in all others, it was done during follow-up after primary surgery. Twelve patients underwent primary surgery in another center and were referred to our clinic for further treatment. As the time between primary surgery and the need for corneal grafting could not be determined reliably from the patients' history, we did not evaluate this in our study.

Eleven of the 16 eyes had undergone multiple surgical procedures on the scleral surface that could predispose to the need for corneal grafting. In 7 eyes, conjunctivo-Tenonplasty with or without amniotic membrane transplantation (AMT) performed before corneal grafting was unsuccessful.

There were no intraoperative complications in any of the eyes. The patients were followed for 6-42 months (mean: 14.37 ± 9.14). Postoperatively, resuturation was necessary in 2 eyes (patients 1 and 2) due to suture loosening and AMT was needed to preserve the corneal graft until epithelialization was completed in 1 eye with a large scleral defect (patient 3). Graft infection, thinning, or immunological rejection and dellen formation were not observed and regrafting was not required in any of the eyes during follow-up. In all eyes, there was sufficient tissue thickness in the covered area and the graft

Table 1. Demographic and clinical characteristics of the patients

Patient #	Sex	Age (years)	Eye	Etiology	Previous surgeries	Lesion size (mm) HxV	Graft size (mm) HxV	Surgical procedure, Graft, Graft thickness (mm)	Preoperative BCVA (LogMAR)	Postoperative BCVA (LogMAR)	Follow-up (months)
1	M	16	Left	Limbal dermoid		8, disc	9, disc	Dermoid excision + 350 µm Microkeratome	0.30	0.30	42
2	F	5	Left	Limbal dermoid	- Dermoid excision - AMT + conjunctivo-tenonplasty	5.5x8.5	6.5x9.5	350 µm Microkeratome	0.10	0.10	21
3	M	63	Right	Scleral melting after MMC pterygium	- Pterygium surgery with MMC and autograft, - Conjunctivoplasty	3.5 and 4, two separate lesions	4 and 5, two separate grafts	300 µm Microkeratome	1.80	0.30	7
4	M	72	Right	Exposed SFIOL superonasal suture	- Cataract surgery - SFIOL, - Conjunctivo-tenonplasty		3x5	Donor corneal rim Partial-thickness	3.10	1.10	6
5	F	26	Left	Melting at the posterior edge of the scleral incision after SFIOL	- Phacoemulsification + sulcus IOL - IOL extraction, SFIOL - DALK	3x5	4x6	Donor corneal rim Partial-thickness	0.40	0.40	17
6	F	36	Left	Post-traumatic	- Primary suturing after trauma	6 disc	7 disc	300 µm Microkeratome	0.52	0.15	12
7	F	35	Right	Traumatic scleral rupture	- Primary suturation - Resuturation + conjunctivo-tenonplasty	2x8	5x10	200 µm Microkeratome	1.30	1.30	6
8	F	79	Right	Scleral melting after repeated glaucoma surgeries	- Trabeculectomy - GDI implantation, - GDI extraction - AMT + conjunctivo-tenonplasty	4.5x7.5	5.5x8.5	Donor corneal rim Full-thickness	1.10	1.10	24
9	M	5	Left	Scleral melting after repeated glaucoma surgeries	- GDI - GDI extraction + dura patch + conjunctivo-tenonplasty	8 disc	9 disc	350 µm Microkeratome	3.10	3.10	13
10	M	40	Right	Scleral defect after trabeculectomy	- Trabeculectomy	6x4.5	7x5	Donor cornea Full-thickness	1.80	1.80	12
11	M	34	Left	Scleral flap defect after trabeculectomy	- Trauma - SFIOL + pupiloplasty - DMEK (twice) - Trabeculectomy	2x1.5	3x2.5	Stroma left over from DMEK surgery, partial-thickness	1.00	1.00	15
12	F	18	Left	Scleral melting after glaucoma surgeries	- GDI - GDI extraction + conjunctivo-tenonplasty	8	7 disc	300 µm Microkeratome	0.10	0.10	13
13	F	55	Right	Exposed GDI	- GDI	2.5x4.5	4x6	300 µm Microkeratome	0.70	0.70	18
14	F	18	Right	Exposed GDI	- GDI	2.5 x4	5x7.5	Stroma left over from DMEK surgery, partial-thickness	0.52	0.52	9
15	F	78	Left	Exposed GDI	- Trabeculectomy - GDI - Phacoemulsification - DMEK	2.5x4	5x7.5	350 µm Microkeratome	3.10	3.10	8
16	F	50	Right	Exposed GDI	- Lensectomy (pediatric) - PKP - GDI	2.5x3	5x7	350 µm Microkeratome	0.70	0.70	7

MMC: Mitomycin C, IOL: Intraocular lens, SFIOL: Scleral fixation intraocular lens, GDI: Glaucoma drainage implant, AMT: Amniotic membrane transplantation, DALK: Deep anterior lamellar keratoplasty, DMEK: Descemet's membrane endothelial keratoplasty, PKP: Penetrating keratoplasty, HxV: Horizontal x vertical, BCVA: Best corrected visual acuity, LogMAR: Logarithmic value of the minimum resolution angle

showed good integration into the recipient tissue and was epithelialized.

The mean visual acuity was 1.22 ± 0.60 logMAR preoperatively and 0.98 ± 0.95 logMAR postoperatively. Tectonic lamellar grafts did not adversely affect final visual acuity in any case. Level of visual acuity did not change in 13 eyes, while an increase from hand movements to 1.10 logMAR was obtained in 1 eye, from 1.80 to 0.30 logMAR in 1 eye, and from 0.52 to 0.15 logMAR in 1 eye.

Discussion

Allogeneic patch grafts are used in cases of scleral tissue loss and exposed glaucoma drainage implants when autologous tissues provide insufficient coverage. When selecting allogeneic materials, desired features include biocompatibility, being immunologically safe, providing a favorable cosmetic appearance, and being easy to obtain, easy to use, and inexpensive. The most commonly used materials are preserved sclera, pericardium, dura mater, amniotic membrane, and donor cornea.^{4,8,10,11,12,13,14,15,16} Many materials are expensive, difficult to obtain, or may not provide a cosmetically acceptable appearance. Amniotic membranes used in recent years reduce scleral melting and accelerate epithelialization but provide weak tectonic support in deep tissue loss.

With preserved sclera, there may be issues regarding sterility and variable quality; it is also thick and not cosmetically preferable. Pericardium tends to melt over extended follow-up. Moreover, pericardium and dura mater are expensive materials.⁴ Corneal tissue is more compact than scleral tissue and is more resistant to recurrent melting and ectasia. In addition, the compact lamellae are more resistant to the spread of infection than sclera.¹⁶ Its transparent structure enables monitoring of the glaucoma drainage implant and for possible complications.

Aside from these advantages, the higher curvature radius of the cornea compared to sclera may cause swelling when placed on a large scleral defect.² Partial-thickness corneal grafts prepared from donor corneas that are not suitable for corneal transplantation provide a more cosmetically satisfying appearance and prevent dellem formation by creating better wound apposition when used near the limbal margin. The transparency of corneal tissue causes the underlying choroidal tissue to appear dark in large and deep defects. Covering with a conjunctival flap and gradual opacification of the graft may improve this appearance.²

Glaucoma drainage implants are frequently used in the surgical treatment of glaucoma. The most important complication of this procedure is erosion of the overlying tissues and subsequent tube exposure. Glaucoma drainage implant exposure can lead to serious vision-threatening complications such as endophthalmitis and hypotony.¹ Therefore, it requires surgical repair or removal. Coverage with simple conjunctival flaps is often inadequate, and once tube erosion occurs, there is greater tendency for recurrent tube erosions.⁶ For this reason, when placing glaucoma drainage implants, many surgeons

prefer to cover the tube with various materials such as preserved sclera, dura mater, pericardium, and donor cornea. Allograft materials tend to erode the conjunctiva over time. Comparative studies and literature data on which of these materials is superior in terms of tube erosion in the long term are still not fully adequate. Favorable results have been reported regarding the use of donor cornea as a patch graft.^{13,16,17,18} Technical variations include the use of glycerol-preserved cornea,¹⁰ gamma-irradiated cornea (VisionGrafts, Tissue Banks International, Baltimore, MD, USA),¹⁹ stromal lenticule obtained in SMILE surgery,¹² and riboflavin-ultraviolet cross-linking to increase resistance to collagenolysis in the long term.^{9,20}

In our study, exposed glaucoma drainage implants were successfully covered with donor corneal grafts in 4 eyes. Because we observed from previous experience that simple conjunctivo-Tenonplasties are inadequate and repeated surgical procedures disrupt the anatomy of the surrounding Tenon's capsule and conjunctiva and lead to deterioration of tube function, no other surgical procedures to cover the glaucoma drainage implant was performed in these cases before using donor cornea.

In repeated glaucoma surgeries, scleral erosion has been reported in the early period or years after trabeculectomy in association with surgical trauma or mitomycin C.¹¹ Ischemia, inflammation, and apoptosis are factors that trigger scleral thinning and necrosis. Scleral defects that occurred after trabeculectomy in 2 eyes and after repeated glaucoma surgeries and/or glaucoma drainage implant removal in 3 eyes were successfully treated with full-thickness or lamellar corneal grafts, depending on defect size and depth (Figure 2b and 3b).

Scleromalacia is an important complication after pterygium surgery, manifesting with scleral thinning, melting, and necrosis. It can occur with all pterygium-related surgical techniques. With the bare sclera technique, it can occur even years after surgery. Although the pathogenesis is not completely clear, the main risk factor is chronic resistance to conjunctival growth over the bare scleral defect.² Changes in the distribution and content of the tear film layer predispose to scleral drying, melting, and secondary infections. Additional treatments such as β radiation, thiotepa, and mitomycin C increase the risk.² Scleral necrosis is observed in 0.2–4.5% of cases.^{9,21,22} In particular, the risk increases with high concentrations and repeated applications of mitomycin C. In our study group, patient 3 underwent pterygium surgery with autograft and mitomycin C followed by cataract surgery 1 year later at another center, after which they developed conjunctival and scleral melting 1 month later. Despite applying conjunctival autografts twice from different parts of the same eye, the areas of scleral melting could not be closed, and the patient was referred to our clinic where he was successfully treated with a partial-thickness donor corneal graft and AMT.

Because limbal dermoids penetrate the cornea, conjunctiva, and scleral tissue, their removal causes tissue defects depending on their size and depth. Excision alone can cause scarring, corneal vascularization, pseudopterygium, and symblepharon.^{23,24,25,26,27} Closing the defect with partial-thickness corneal grafts after

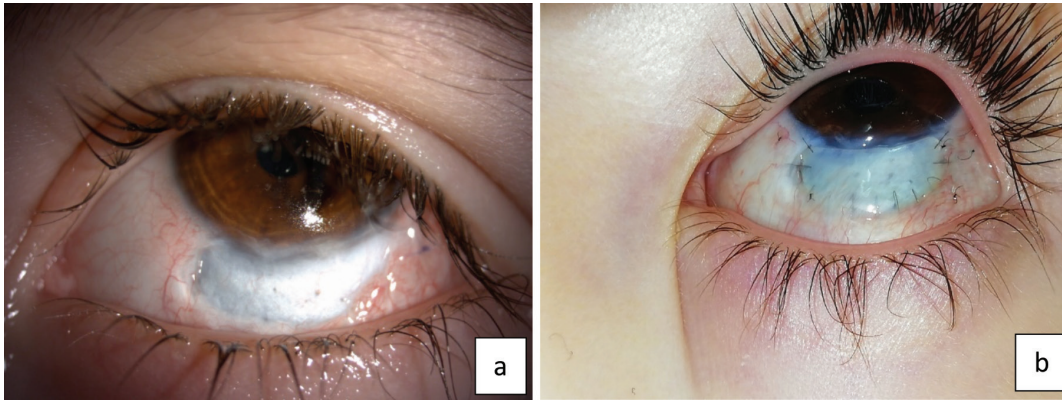


Figure 1. Patient 2, aged 5 years, underwent dermoid excision in another center 15 months earlier and developed scleral melting that could not be treated with conjunctivo-Tenonplasty and amniotic membrane transplantation; a) before corneal patch grafting, b) 6 months after patch grafting

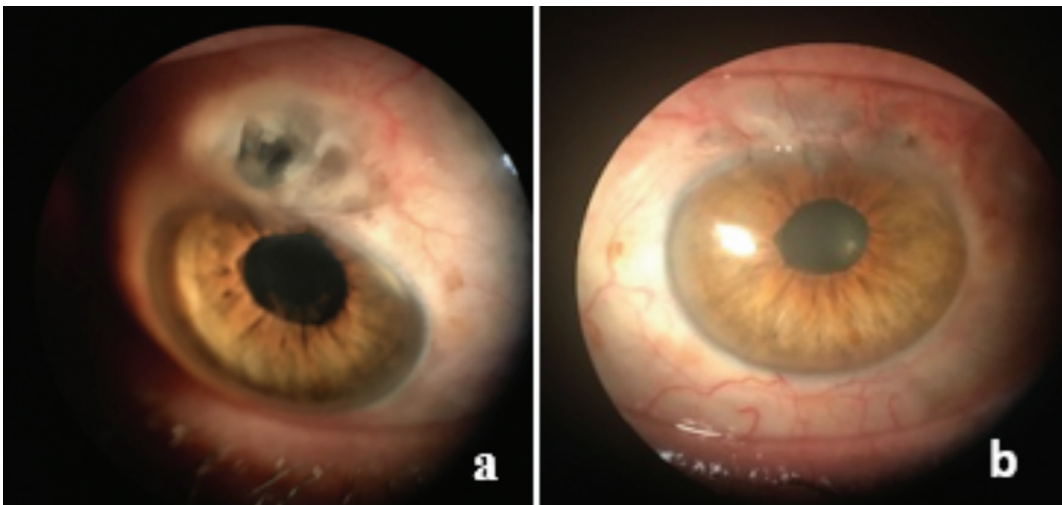


Figure 2. Patient 10, a 40-year-old man, referred from another center due to large scleral defect after glaucoma surgery; a) preoperative, b) postoperative, 3 months after defect closure with 7x5 mm full-thickness donor cornea

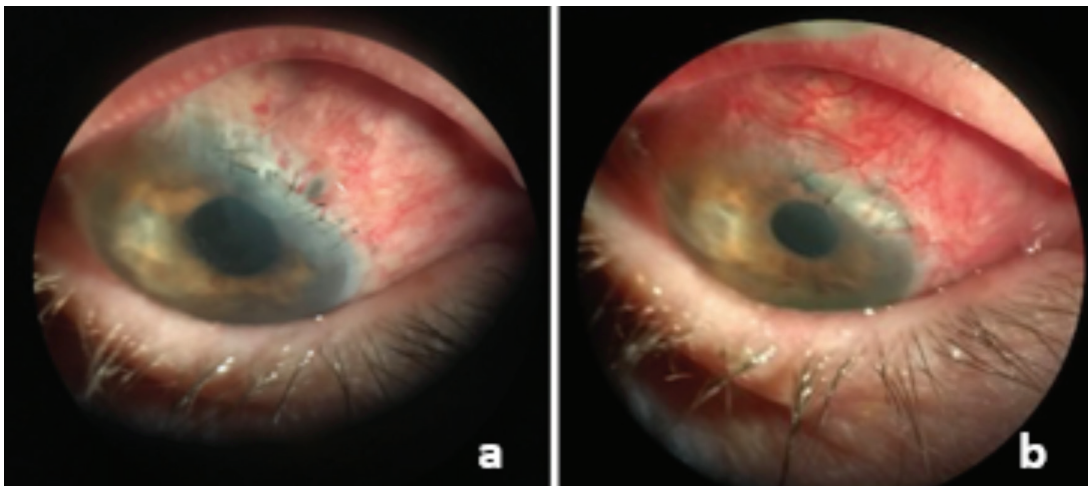


Figure 3. Patient 13, a 55-year-old woman, with exposed Ahmed glaucoma valve implant; a) insufficient conjunctivo-Tenonplasty before patch grafting, b) after grafting with a 300 µm patch graft prepared with Moria microkeratome

resection reduces the development of these complications and creates a more cosmetically pleasing appearance.^{26,27} AMT and conjunctivo-Tenonplasty was performed in the same session as dermoid excision in patient 1 and approximately 15 months after dermoid excision performed in another center in an attempt to close the area of scleral melting in patient 2. When adequate results could not be obtained, the patients were referred to our center and underwent donor corneal grafting (Figure 1b).

In SFIOL implantations, inadequate suture coverage and suture exposure due to tissue erosion are the most important complications.^{28,29} Microorganisms can enter the eye through the suture tract and cause endophthalmitis. Because fibrosis does not occur between the ciliary body and the haptic, removing the exposed suture is not recommended. If possible, the knot should be surgically repositioned, embedded under the sclera, or covered with scleral or corneal patch grafts.²⁹ Patient 4 in our study group underwent SFIOL surgery in another center 2 years earlier and the exposed SFIOL suture was closed with a partial-thickness donor corneal graft after failed conjunctivo-Tenonplasty.

In phacoemulsification surgery, corneal and scleral thermal damage can denature the collagen and the tissue opacifies and contracts, preventing adequate wound closure. The wound edges assume a “fish-mouth” appearance that leads to postoperative wound leakage.^{30,31} Patient 5, who was also referred from another center, had undergone IOL removal via a corneoscleral incision, anterior vitrectomy, and SFIOL implantation. After deep anterior lamellar keratoplasty due to macular dystrophy 3 months later, a gradually increasing conjunctival bleb was noted during follow-up. Exploration of the conjunctiva at 10 months revealed melting of the posterior edge of the corneoscleral incision, and the incision site was covered with a watertight lamellar corneal graft. As ultrasonic energy was not used in this case, thermal damage was not considered the cause. There were no pathological findings in autoimmune investigations that could cause scleral melting.

To avoid the less favorable cosmetic appearance of full-thickness corneal grafts, prevent dellen formation in lesions near the limbus, and achieve a more natural corneoscleral limbal appearance, we preferred to use partial-thickness lamellar corneal grafts to cover the glaucoma drainage implant in cases close to the limbus. If a donor corneal rim or the remaining corneal stroma from DMEK was used, lamellar grafts were prepared manually to approximately half thickness and no cosmetic problems occurred in any case. Grafts prepared with the Moria ALTK system, which is an expensive system, were made at the desired thickness with a smooth surface cut. In addition, beveled edge of the grafts, similar to LASIK flaps, provided a smooth recipient-donor junction with no elevation, especially when used near the limbus. During the follow-up period, none of the lamellar grafts prepared manually or with the automated system or the full-thickness grafts used in deep tissue loss created a cosmetically unacceptable appearance or dellen formation.

In our cases with scleral tissue loss or glaucoma drainage implant erosion caused by various pathologies, the use of corneal

grafts provided good ocular surface restoration and cosmetic appearance with a maximum follow-up period of 42 months. The use of partial- or full-thickness corneal grafts in scleral tissue loss due to various causes resulted in anatomically successful restoration of global integrity as well as good graft-recipient apposition and favorable cosmesis.

Study Limitations

Limitations of the study were that other patch graft materials could not be compared in long-term follow-up due to the small number of patients with scleral defects, many of which developed as complications. The strength of the study is that our evaluation of the use of left-over donor corneal tissues for scleral surface reconstructions associated with different etiologies and the transfer of surgical experience can shed light on other studies.

Conclusion

Donor corneal rims left over from keratoplasty, stromal grafts remaining after using the endothelium for DMEK, seronegative grafts not suitable for optical corneal transplantation, and corneal tissues removed during keratoplasty can be used for the reconstruction of scleral surface pathologies of varying etiology. Long-term graft viability should be investigated in large patient series with long follow-up periods to determine whether the method is effective and safe in terms of graft failure.

Ethics

Ethics Committee Approval: The study was approved by the Clinical Research Ethics Committee of University of Health Sciences Turkey Ankara Training and Research Hospital (study e. kurul-E-20/307).

Informed Consent: Obtained.

Peer-review: Externally peer reviewed.

Authorship Contributions

Surgical and Medical Practices: A.B., Z.Y.A., Concept: A.B., Design: A.B., Data Collection or Processing: A.B., Z.Y.A., E.Ş.Ö., S.Ö.U., Analysis or Interpretation: A.B., Literature Search: A.B., Writing: A.B.

Conflict of Interest: No conflict of interest was declared by the authors.

Financial Disclosure: The authors declared that this study received no financial support.

References

- Gedde SJ, Scott IU, Tabandeh H, Luu KK, Budenz DL, Greenfield DS, Flaynn Jr HW. Late endophthalmitis associated with glaucoma drainage implants. *Ophthalmology*. 2001;108:1323-1327.
- Ti SE, Tan DT. Tectonic Corneal Lamellar Grafting for Severe Scleral Melting After Pterygium Surgery. *Ophthalmology*. 2003;110:1126-1136.
- Singh M, Chew PT, Tan D. Corneal patch graft repair of exposed glaucoma drainage implants. *Cornea*. 2008;27:1171-1173.
- Smith MF, Doyle JW, Tierney JW Jr. A comparison of glaucoma drainage implant tube coverage. *J Glaucoma*. 2002;11:143-147.
- Lankaranian D, Reis R, Henderer JD, Choe S, Moster MR. Comparison of single thickness and double thickness processed pericardium patch graft in glaucoma drainage device surgery: a single surgeon comparison of outcome. *J Glaucoma*. 2008;17:48-51.

6. Tamcelik N, Ozkok A, Sarıcı AM, Atalay E, Yetik H, Gungor K. Tenon advancement and duplication technique to prevent postoperative Ahmed valve tube exposure in patients with refractory glaucoma. *Jpn J Ophthalmol*. 2013;57:359-364.
7. Lind JT, Shute TS, Sheybani A. Patch graft materials for glaucoma tube implants. *Curr Opin Ophthalmol*. 2017;28:194-198.
8. Zalta AH. Long-term experience of patch graft failure after ahmed glaucoma valve surgery using donor dura and sclera allografts. *Ophthalmic Surg Lasers Imaging*. 2012;43:408-415.
9. Stone DU, Craven ER, Ahmad SI, AlBeshri A, Owaidhah OA. Glaucoma Patch Graft Surgery Utilizing Corneas Augmented with Collagen Cross-linking. *Middle East Afr J Ophthalmol*. 2019;26:148-152.
10. Wigton E, C Swanner J, Joiner W, Feldman A, McGwin G Jr, Huisingsh C, Curcio CA, Girkin CA. Outcomes of shunt tube coverage with glycerol preserved cornea versus pericardium. *J Glaucoma*. 2014;23:258-261.
11. Coutinho I, Silva D, Mota M, Lisboa M, Trancoso Vaz F, Prieto I. Reconstruction of delayed scleral flap melting with bovine pericardium after trabeculectomy with mitomycin C. *GMS Ophthalmol Cases*. 2017;7:15.
12. Song YJ, Kim S, Yoon GJ. Case series: Use of stromal lenticule as patch graft. *Am J Ophthalmol Case Rep*. 2018;12:79-82.
13. Ahmed SF, Schmutz M, Mosaed S. Case Series: Keratolimbic Allograft as a Patch Graft for Glaucoma Drainage Devices. *J Glaucoma*. 2017;26:205-209.
14. Wang Y, Li X, Huang W, Liu J, Xu Y, Chen M, Wang Q. Partial thickness cornea tissue from small incision lenticule extraction: A novel patch graft in glaucoma drainage implant surgery. *Medicine (Baltimore)* 2019;98:e14500.
15. Thakur S, Ichhpujani P, Kumar S. Grafts in Glaucoma Surgery: A Review of the Literature. *Asia Pac J Ophthalmol (Phila)*. 2017;6:469-476.
16. Spierer O, Waisbourd M, Golan Y, Newman H, Rachmiel R. Partial thickness corneal tissue as a patch graft material for prevention of glaucoma drainage device exposure. *BMC Ophthalmol*. 2016;16:20.
17. Fukuchi T, Matsuda H, Ueda J, Yamada A, Suda K, Abe H. Corneal lamellar grafting to repair late complications of mitomycin C trabeculectomy. *Clin Ophthalmol*. 2010;4:197-202.
18. Bochmann F, Kaufmann C, Kipfer A, Thiel MA. Corneal patch graft for the repair of late-onset hypotony or filtering bleb leak after trabeculectomy: a new surgical technique. *J Glaucoma*. 2014;23:76-80.
19. Ekici F, Moster MR, Cvintal V, Hu WD, Waisbourd M. Tube shunt coverage with gamma-irradiated cornea allograft (VisionGraft). *Clin Ophthalmol*. 2015;9:751-755.
20. Arafat SN, Robert MC, Shukla AN, Dohlman CH, Chodosh J, Ciolino JB. UV cross-linking of donor corneas confers resistance to keratolysis. *Cornea*. 2014;33:955-959.
21. Tarr KH, Constable IJ. Late complications of pterygium treatment. *Br J Ophthalmol*. 1980;64:496-505.
22. Sullivan LJ, Snibson G, Joseph C, Taylor HR. *Scedosporium prolificans* sclerokeratitis. *Aust N Z J Ophthalmol*. 1994;22:207-209.
23. Panton RW, Sugar J. Excision of limbal dermoids. *Ophthalmic Surg*. 1991;22:85-89.
24. Panda A, Ghose S, Khokhar S, Das H. Surgical outcomes of Epibulbar dermoids. *J Pediatr Ophthalmol Strabismus*. 2002;39:20-25.
25. Yao Y, Zhang MZ, Jhanji V. Surgical management of limbal dermoids: 10-year review. *Acta Ophthalmol*. 2017;95:517-518.
26. Spierer O, Gologorsky D, Adler E, Forster RK. Lamellar keratoplasty with corneoscleral graft for limbal dermoids. *Int J Ophthalmol*. 2018;11:512-515.
27. Zhou AX, Ambati BK. Sutureless Lamellar Corneoscleral Patch Graft With Fibrin Sealant for Limbal Dermoid Removal. *J Pediatr Ophthalmol Strabismus*. 2016;53:22-25.
28. Davies EC, Pineda R 2nd. Complications of Scleral-Fixated Intraocular Lenses. *Semin Ophthalmol*. 2018;33:23-28.
29. Bucci FA Jr, Holland EJ, Lindstrom RL. Corneal Autografts for External Knots in Transsclerally Sutured Posterior Chamber Lenses. *Am J Ophthalmol*. 1991;112:353-354.
30. Ernest P, Rhem M, McDermott M, Lavery K, Sensoli A. Phacoemulsification conditions resulting in thermal wound injury. *J Cataract Refract Surg*. 2001;27:1829-1839.
31. Sippel KC, Pineda R Jr. Phacoemulsification and thermal wound injury. *Semin Ophthalmol*. 2002;17:102-109.