



Clinical and Mycological Features of Fungal Keratitis: A Retrospective Single-Center Study (2012-2018)

İbrahim İnan Harbiyeli*, Elif Erdem*, Nuhkan Görkemli*, Astan İbayev*, Hazal Kandemir**, Arbil Açıklalın***, Macit İlkit**, Meltem Yağmur*

*Çukurova University Faculty of Medicine, Department of Ophthalmology, Adana, Turkey

**Çukurova University Faculty of Medicine, Department of Microbiology, Division of Mycology, Adana, Turkey

***Çukurova University Faculty of Medicine, Department of Patology, Adana, Turkey

Abstract

Objectives: To present the demographic, etiological, clinical, and mycological characteristics and treatment results of fungal keratitis patients admitted to our clinic.

Materials and Methods: The medical records of patients diagnosed with fungal keratitis between October 2012 and 2018 were reviewed. The diagnosis of fungal keratitis was confirmed mycologically and/or cytologically. Treatment response was defined as complete infiltrate resolution and re-epithelization with medical treatment and minor surgical interventions. Patients who underwent penetrating keratoplasty or evisceration due to clinical deterioration despite treatment were classified as treatment nonresponders and were compared with responders in terms of demographic, etiological, and clinical characteristics.

Results: Seventy-two (12.8%) of 559 patients diagnosed with microbial keratitis in the 6-year period were fungal keratitis. Of these, 38 cases (38 eyes) without polymicrobial etiology were included in the study. The patients' mean age was 44.9 ± 19.0 years (range: 2-80) and males predominated (14 females [36.8%], 24 males [63.2%]). Trauma (63.6%) was the most common predisposing factor in patients younger than 40 years old, whereas pathologies impairing ocular surface immunity were the leading risk factor (48.1%) in patients older than 40 years. Filamentous fungi were detected in 34 (89.5%) cases, while yeasts were found in 4 (10.5%) cases. Among 26 cases with positive cultures, *Aspergillus* species were the most common pathogens (42.3%). Infiltrate size before treatment was larger in nonresponders (14/38, 36.8%) compared to treatment responders (19/38, 50%) ($p=0.049$). In addition, rates of treatment response were higher in cases in which the infiltrate was located paracentrally compared to other cases ($p=0.036$).

Conclusion: Fungal keratitis is an important public health problem in our region. Ocular trauma is a leading etiology in men under the age of 40 years. In the 6-year period, we observed that the main causes of fungal keratitis were filamentous fungi, and most commonly *Aspergillus* species. In cases presenting with large and central lesions, aggressive treatment options should be considered and these patients should be followed up more closely.

Keywords: *Aspergillus*, *Candida*, *Fusarium*, filamentous fungus, fungal keratitis, yeast fungus

Address for Correspondence: İbrahim İnan Harbiyeli, Çukurova University Faculty of Medicine, Department of Ophthalmology, Adana, Turkey

E-mail: iharbiyeli@cu.edu.tr **ORCID-ID:** orcid.org/0000-0003-2586-1096

Received: 13.03.2021 **Accepted:** 26.05.2021

Cite this article as: Harbiyeli İİ, Erdem E, Görkemli N, İbayev A, Kandemir H, Açıklalın A, İlkit M, Yağmur M. Clinical and Mycological Features of Fungal Keratitis: A Retrospective Single-Center Study (2012-2018). Turk J Ophthalmol 2022;52:75-85

Introduction

Infectious keratitis is one of the leading causes of unilateral blindness worldwide.¹ Among infectious keratitis etiologies, fungal keratitis is less common than bacterial keratitis but poses a greater threat to vision. In fungal keratitis, the main diagnostic challenges are that clinical diagnosis requires experience, and cytological examination and fungal cultures involve a meticulous and relatively long process, while the major therapeutic challenges include the low corneal penetration and generally fungistatic nature of antifungal drugs, and variations in drug sensitivity among fungal pathogens.^{1,2} These difficulties lead to a poorer prognosis and 5- to 6-fold higher prevalence of corneal perforation than in bacterial keratitis.^{3,4} Therefore, early diagnosis and effective treatment of fungal keratitis are essential.¹

The prevalence of fungal keratitis, the causative microorganisms, and associated risk factors vary by geographic region.² In tropical and subtropical regions, where the incidence is high and the etiology is often traumatic, molds are the leading pathogen, whereas in colder and drier climates, the etiology usually involves factors that impair ocular surface immunity and yeasts are the predominant pathogens.^{2,5} Regional variations in the epidemiology of fungal keratitis and the difficulty of treating these infections increase the importance of results reported from referral centers in different geographical regions.

This study aimed to present the demographic, etiological, clinical, and mycological characteristics and treatment results of fungal keratitis patients admitted to a tertiary referral center in southern Turkey over a 6-year period.

Materials and Methods

The medical records of patients diagnosed with microbial keratitis in the cornea unit of the Çukurova University Faculty of Medicine, Department of Ophthalmology between October 2012 and October 2018 were retrospectively analyzed. Of the patients with a fungal pathogen demonstrated by culture and/or cytological examination, those with complete medical records were included in the study. The presence of endophthalmitis at admission was accepted as the exclusion criterion. The study was approved by the Çukurova University Faculty of Medicine Ethics Committee (date: 03.07.2020, meeting/decision no: 101/12) and the study was conducted in accordance with the principles of the Declaration of Helsinki. Demographic and etiological characteristics, symptom duration, risk factors, systemic comorbidities, causative microorganisms and diagnostic methods, pre-treatment best corrected visual acuity, infiltration characteristics and presence of hypopyon at presentation, treatments, and treatment results were recorded. Infiltrate location was recorded as central, paracentral, or peripheral.⁶ Infiltrate depth was assessed biomicroscopically and classified as superficial (less than two-thirds of the corneal thickness) or deep (more than two-thirds of the corneal thickness).⁶

Cytological and Mycological Examination

Under topical anesthesia, scraping samples were obtained from the base and margins of all infiltrates. The clinical specimens were examined by direct microscopy in the pathology

department of the Çukurova University Faculty of Medicine. The presence of epithelial cells and associated fungal hyphens in the samples was investigated using Papanicolaou and periodic acid-Schiff stains. Samples in liquid brain-heart infusion (bioMérieux, Marcy l'Etoile, France) transport medium were delivered to the Medical Mycology unit of the Çukurova University School of Medicine, Department of Microbiology and inoculated onto appropriate culture media (blood agar [bioMérieux], Sabouraud-glucose agar [Merck, Darmstadt, Germany], potato dextrose agar [Merck], and brain-heart infusion agar [bioMérieux]) using a "C" streak. The plates were incubated at 28 °C and 37 °C and examined for growth.

The molecular diagnosis of isolated fungi was made in the Westerdijk Fungal Biodiversity Institute in Utrecht, Netherlands. *Aspergillus* species were identified using primers targeting the rDNA internal transcribed spacer (ITS) and partial calmodulin gene regions, and *Fusarium* species were identified using primers targeting the partial elongation factor 1-alpha (tef1-alpha) gene region.^{7,8} All isolates were stored under their Centraalbureau voor Schimmelcultures (CBS; Utrecht, Netherlands) or Macit İlkit Working Collection (MI; Adana, Turkey) registration numbers.

Treatment

In all cases of microbial keratitis, treatment was initiated empirically. Empirical topical treatment consisted of combination fortified vancomycin (50 mg/mL; Kocak, Istanbul, Turkey)/amikacin (50 mg/mL; Osel, Istanbul, Turkey) or moxifloxacin (0.5%; Vigamox, Alcon, Fort Worth, USA), depending on the severity of clinical findings. If fungal keratitis was strongly suspected based on medical history and clinical findings, topical fortified voriconazole (10 mg/mL; Vfend, Pfizer, New York, USA) was added to the empirical treatment without waiting for laboratory results. The subsequent treatment protocol was modified according to clinical response and the results of microbiological examination.

In patients whose cytological examination and/or culture yielded a fungal pathogen, a topical antifungal agent (fortified voriconazole or amphotericin B [when *Aspergillus* species or yeast infection is detected] 2.5 mg/mL; AmBisome, NeXstar Pharmaceuticals, San Dimas, USA) hourly was added to the treatment if it had not been initiated empirically. In patients with positive fungal culture, antifungal treatment was changed according to the species of microorganism detected. In *Fusarium* cases, if the patient did not respond to the antifungal treatment initiated, topical posaconazole (10 mg/0.1 mL; Noxafil, Schering Plough, New Jersey, USA) was added, and in the presence of yeast infection, caspofungin (10 mg/mL; Cancidas, Merck Sharp Dohme, New Jersey, USA) was added to treatment. Systemic administration of antifungal drugs selected according to the pathogen, intrastromal and/or intracameral voriconazole or amphotericin B injections, and corneal cross-linking (CXL) were performed as needed based on the severity of clinical findings and response to treatment. In all cases, the frequency and duration of treatment were determined according to the clinical response observed during follow-up. In cases where

medical treatment was inadequate, various surgical treatments (amniotic membrane transplantation [AMT], corneal patch graft, penetrating keratoplasty [PK], and evisceration) were performed.

Treatment response was defined as complete infiltrate resolution and re-epithelialization after medical treatment and minor surgical interventions (AMT, corneal patch graft). Patients who discontinued clinical follow-up after recovery (post-recovery follow-up period <2 weeks) or did not show complete resolution at their last examination were evaluated as having insufficient clinical follow-up. Patients in whom progression of the infection could not be halted despite all treatments and those who underwent PK or evisceration were classified as nonresponsive to treatment. Demographic, etiological, and clinical characteristics were compared between patients whose clinical follow-up period and post-treatment findings met the criteria for treatment response and those who were nonresponsive. In addition, an increase of 1 or more Snellen lines after treatment compared to initial visual acuity was considered visual improvement with treatment. Treatment responders with and without visual improvement with treatment were compared.

Statistical Analysis

SPSS version 25.0 software package (IBM Corp., Armonk, NY, USA) was used for statistical analyses. Categorical values were summarized as frequency and percentage; continuous data were summarized as mean and standard deviation (or median, minimum, and maximum, as appropriate). Chi-square test or Fisher test statistic was used to compare categorical variables. For between-group comparisons of continuous measures, data distributions were tested and Student’s t-test was used for normally distributed variables and Mann-Whitney U test was used for non-normally distributed variables. Independent risk factors associated with treatment outcome were identified using logistic regression analysis. The level of significance was accepted as 0.05 for all tests.

Results

Of 559 patients diagnosed with microbial keratitis within the 6-year study period, 72 (12.8%) had fungal keratitis. Seven patients whose medical records were not fully accessible were excluded. Of the remaining 65 patients, 27 (41.5%) had polymicrobial etiology and were reported in a previous study.⁹ As a result, 38 cases of fungal keratitis not accompanied by another type of microbial agent were included in this study. The mean age of the patients was 44.9±19.0 years (range: 2-80). Male patients outnumbered females (14 females [36.8%], 24 males [63.2%]) and this male predominance was more pronounced among patients under 40 years of age (8/11, 72.7%). When examined in terms of age distribution, most patients were 40-60 years of age (n=20, 52.6%) (Figure 1). Case numbers were higher in 2012 and 2018 and evenly distributed among the other years (Figure 2). When the seasonal distribution of patient admissions was examined, we observed that most cases presented during the fall (n=16, 42.1%) (Figure 3).

The most common predisposing factor was trauma, present in 17 patients (44.7%) (Table 1). Ten (10/17; 58.8%) of these patients had plant- or animal-related trauma. Diabetes mellitus was the most common systemic risk factor (n=8, 18.2%), while no predisposing factor was identified in 9 patients (23.7%). Predisposing factors were evenly distributed according to season and year of presentation but differed by age group. The most common predisposing factors were trauma before the age of 40 years (7/11, 63.6%) and local and systemic pathologies impairing ocular surface immunity after the age of 40 years (13/27, 48.1%).

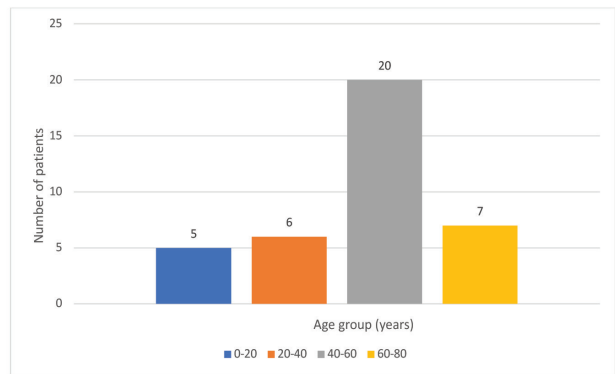


Figure 1. Age distribution of the patients

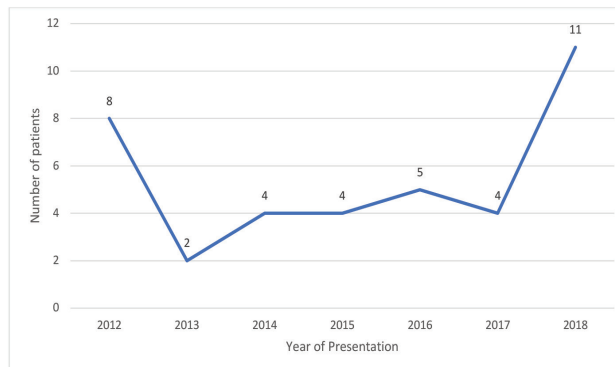


Figure 2. Distribution of cases by year of presentation

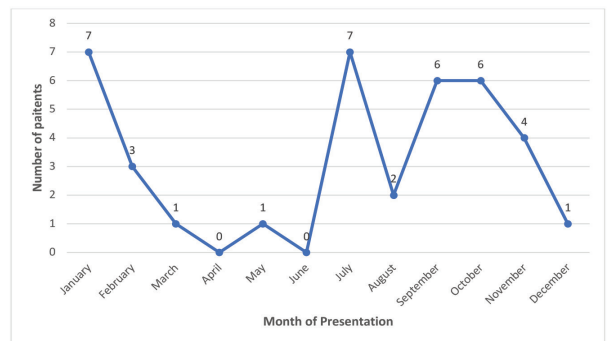


Figure 3. Distribution of cases by month of presentation

The causative microorganism was detected by fungal culture in 26 patients (68.4%) and both fungal culture and cytological examination in 15 patients (39.4%). In the 12 patients (31.6%) with negative fungal culture, the diagnosis was made by cytological examination. Molds were detected in 34 patients (89.5%) and yeasts were detected in 4 patients (10.5%) (Table 2). The epidemiological and clinical characteristics of the two fungal groups at presentation are shown in Table 3. The most common pathogens detected in the 26 patients with positive cultures were *Aspergillus* species (11/26, 42.3%). There was no significant difference between fungal isolates in terms of epidemiological and clinical characteristics at presentation ($p>0.05$ for all).

The median symptom duration before presentation was 15 days (range: 1-120). The mean infiltrate area at presentation was $38.2 \pm 30.2 \text{ mm}^2$ (range: 1.3-143.7; $n=36$, could not be measured in 2 patients). When the patients were examined in terms of lesion characteristics, 14 patients (36.8%) had satellite infiltrates, 5 (13.2%) had ring infiltrates, and 16 (42.1%) had hypopyon. Infiltrates were superficial in 11 patients (28.9%) and deep in 27 patients (71.1%). Infiltrate location was central in 22 patients (57.9%), paracentral in 14 patients (36.8%), and peripheral in 2 patients (5.3%). Ten patients (26.3%) received only topical antifungal therapy. In addition to topical treatment, 22 patients (57.8%) received systemic antifungal therapy, 20 (52.6%) received intrastromal antifungal (amphotericin or voriconazole) injections, and 5 patients (13%) underwent CXL. Antifungal therapy could not be administered to 1 patient who had corneal perforation and underwent evisceration before the

results of corneal specimen examination were available. During follow-up, AMT was performed in 15 patients (39.5%) and corneal patch grafting was performed in 4 patients (10.5%). After these treatments, 19 patients (50%) with a mean follow-up time of 19.5 months (range: 1-65) demonstrated complete infiltrate resolution and re-epithelialization, with persistence of these findings for at least 2 weeks (treatment responders). In 14 patients (36.8%), progression of the infection could not be halted despite all treatments (non-responders). Eight (21%) of these patients underwent PK and 6 (15.8%) underwent evisceration. In 2 of the 6 patients who underwent evisceration, long symptom duration and late presentation to our clinic (26 and 30 days) contributed to the poor prognosis. In another patient who had corneal perforation at presentation and developed endophthalmitis within the first week of clinical follow-up, tectonic surgery was not possible and evisceration was performed. In the other patients, infections extending to the limbus and sclera or spreading to the posterior segment despite antifungal therapy precluded PK.

Comparison of treatment responders and nonresponders showed that initial infiltrate area was larger in nonresponders ($p=0.049$; Table 4). In addition, the response rate was higher among patients with paracentral infiltrates than in other patients ($p=0.036$). Because a larger infiltrate area increases the risk of the lesion involving the central cornea, these variables were evaluated in a logistic regression model to determine whether the relationship between infiltrate location and treatment response was affected by lesion size. This analysis revealed that lesion location was an independent parameter associated

Table 1. Predisposing factors identified in fungal keratitis cases

Predisposing factor	Number of patients	Percentage
Trauma	17	38.6
Plant injury (branch, thorn, grass)	8	18.2
Animal injury (horn, tail)	2	4.5
Other (metal, stone, dust)	7	15.9
Risk factors impairing ocular surface immunity	25	56.8
Local factors	15	34.1
Chronic ocular surface disease [†]	7	15.9
Topical steroid use	3	6.8
Previous ocular surface surgery [‡]	4	9.1
Long-term topical drug use (>6 months) [§]	1	2.3
Systemic diseases	10	22.7
DM	8	18.2
Other [¶]	2	4.5
Contact lens use	2	4.6
Total	44 [*]	100

[†]Chronic blepharitis, dry eye, atopic keratoconjunctivitis, herpes simplex keratitis, lagophthalmic keratopathy

[‡]Penetrating keratoplasty, pterygium surgery, pars plana vitrectomy

[§]Topical antiglaucoma, topical antibiotic

[¶]Bullous pemphigoid, immunodeficiency secondary to genetic syndrome

^{*}Seven patients had multiple factors that impaired ocular surface immunity.

Table 2. Data related to the fungal isolates		
Fungal isolates	Isolate number (%)	CBS/MI no.
Molds	34 (89.5)	
Cytologic diagnosis	12 (31.5)	
Culture diagnosis	22 (57.8)	
<i>Aspergillus</i> species	11 (28.9)	
<i>Aspergillus fumigatus</i>	4 (10.5)	CBS 145410/CBS 145409/MI 198905
<i>Aspergillus flavus</i>	3 (7.8)	
<i>Aspergillus terreus</i>	1 (2.6)	CBS 135845
<i>Aspergillus</i> spp.	3 (7.8)	
<i>Fusarium</i> species	8 (21)	
<i>Fusarium solani</i>	3 (7.8)	CBS 143255/CBS 138564/MI 198906
<i>Fusarium falciforme</i>	2 (5.2)	CBS 198901/CBS 143254
<i>Fusarium</i> spp.	3 (7.8)	CBS 145411
Unidentified black fungus	1 (2.6)	
Unidentified mold	2 (5.2)	
Yeasts	4 (10.5)	
Cytologic diagnosis	None	
Culture diagnosis	4 (10.5)	
<i>Candida</i> species	3 (7.8)	
<i>Candida tropicalis</i>	1 (2.6)	
<i>Candida</i> spp.	2 (5.2)	
Unidentified yeast	1 (2.6)	
Total isolates	38 (100)	

CBS: Centraalbureau voor Schimmelcultures, MI: Macit Ilkit Working Collection

with treatment response rate (odds ratio: 6.6, 95% confidence interval: 1.1-42; $p=0.048$). Five patients (13.2%) were evaluated as having insufficient clinical follow-up and their data were not included in the analysis of treatment outcome.

At initial presentation, vision level was between light perception and hand movements in 23 patients, counting fingers at 1-5 meters in 2 patients, and ≥ 0.1 (Snellen, decimal) in 10 patients. One patient had no light perception at presentation, while visual acuity could not be evaluated in 2 cases (1 child and 1 patient with cognitive disability). Among the treatment responders ($n=19$), 8 patients (42.1%) had a visual improvement of 1 Snellen line or more at final post-treatment examination compared to their visual acuity at initial presentation. Visual acuity after treatment was unchanged in 6 patients (31.5%) and declined in 3 patients (15.7%) compared to pre-treatment levels (visual acuity could not be measured in 1 pediatric patient; the patient with no light perception was not included in the evaluation). The 8 patients with visual improvement after treatment were compared with the other 9 patients in terms

of data at initial presentation, but there was no statistically significant difference between the two groups in terms of demographic or clinical parameters ($p>0.05$ for all). Four (50%) of the patients that underwent PK showed visual improvement of 1 or more Snellen lines at last examination compared to presentation. Visual acuity remained unchanged after PK in 2 patients (25%) and declined in the other 2 patients (25%).

Discussion

Fungal keratitis is one of the leading causes of vision loss in developing countries.¹ Difficulties in both mycological and clinical diagnosis and the limited efficacy of antifungal drugs may result in reduced treatment success and unfavorable visual outcomes in these infections.¹⁰ This study presents detailed data regarding the demographic characteristics, predisposing factors, causative microorganisms, and treatment results in fungal keratitis cases from a referral center with experience in fungal keratitis.

	Mold (n=34)		Yeast (n=4)	
	n	%	n	%
Sex				
F	12	35.3	2	50.0
M	22	64.7	2	50.0
Year of presentation				
2012-2015	18	52.9	0	0.0
2016-2018	16	47.1	4	100.0
Season of presentation				
Spring	2	5.9	0	0.0
Summer	9	26.5	0	0.0
Fall	15	44.1	1	25.0
Winter	8	23.5	3	75.0
Predisposing factor				
Trauma	12	35.3	1	25.0
Conditions impairing ocular surface immunity	8	23.5	3	75.0
Contact lens use	1	2.9	0	0.0
Multiple factors	5	14.7	0	0.0
None identified	8	23.5	0	0.0
Hypopyon	14	41.2	2	50.0
Central lesion	20	58.8	2	50.0
Deep lesion	25	73.5	2	50.0
Satellite lesion	13	38.2	1	25.0
Ring infiltrate	5	14.7	0	0.0
Baseline visual level[†]				
≤Hand motions	22	66.6	2	66.7
Counting fingers at 1-5 m	4	12.1	1	33.3
0.1-1 Snellen decimal	7	21.2	0	0.0
	Mean ± SD (min-max)		Mean ± SD (min-max)	
Age (years)	46±18.33 (7-80)		55±27.86 (2-62)	
Symptom duration	13±25.65 (1-120)		22±10.9 (13-35)	
Infiltrate area[‡]	30±34.68 (1.3-143.7)		20.2±19.12 (16.4-20.2)	

There were no statistically significant differences in the shown variables among the fungal species. Due to the small number of cases associated with yeasts, p values are not included in the table.

[†]Vision level could not be evaluated in 1 patient from each group.

[‡]Infiltrate area could not be measured in 2 patients.

SD: Standard deviation, min: Minimum, max: Maximum

The prevalence of fungal keratitis varies regionally according to socioeconomic profile, climate, and environmental conditions.¹¹ Fungal infections constitute a substantial proportion of microbial keratitis cases, especially in areas with large populations of agricultural workers and in hot, humid areas.¹ Different studies in India have reported that they account for 8% to 47% of all cases of infectious keratitis.^{11,12} In a study examining microbial keratitis in a center in western Turkey, Yilmaz et

al.¹³ reported the prevalence of fungal keratitis to be 24.2%. Hilmioglu-Polat et al.¹⁴ estimated the annual incidence of fungal keratitis in Turkey as 33/100,000. The Çukurova region has a subtropical climate and extensive agricultural land use, resulting in a geographic predisposition to fungal infections. This study includes data from a tertiary hospital in this region and showed that the rate of fungal keratitis was 12.8% among 559 cases of microbial keratitis over a 6-year period.

	Treatment outcome [¶]				p
	Treatment response (n=19)		Treatment non-response (n=14)		
	n	%	n	%	
Sex					
F	7	36.8	5	35.7	1
M	12	63.2	9	64.3	
Year of presentation					
2012-2015	10	52.6	5	35.7	0.482
2016-2018	9	47.4	9	64.3	
Season of presentation					
Spring	1	5.3	1	7.1	0.755
Summer	4	21.1	4	28.6	
Fall	9	47.4	4	28.6	
Winter	5	26.3	5	35.7	
Predisposing factor					
Trauma	4	21.1	6	42.9	0.218
Conditions impairing ocular surface immunity	7	36.8	2	14.3	
Contact lens use	0	0.0	1	7.1	
Multiple factors	2	10.5	3	21.4	
None identified	6	31.6	2	14.3	
Fungal species					
Mold [§]	17	89.5	13	92.9	0.616
<i>Fusarium</i>	2	10.5	4	28.6	
<i>Aspergillus</i>	7	36.8	4	28.6	
Yeast	2	10.5	1	7.1	
Hypopyon	7	36.8	7	50.0	0.497
Central lesion	8	42.1	12	85.7	0.036
Deep lesion	12	63.2	10	71.4	0.719
Satellite lesion	6	31.6	5	35.7	1
Ring infiltrate	2	10.5	2	14.3	1
Baseline visual level [‡]					
≤ Hand motions	10	55.6	12	92.3	0.086
Counting fingers at 1-5 m	4	22.2	1	7.7	
0.1-1 Snellen decimal	4	22.2	0	0.0	
	Mean ± SD (min-max)		Mean ± SD (min-max)		
Age (years)	47±20.41 (2-80)		47±16.08 (7-45)		0.747
Symptom duration	10±17 (1-60)		20±21.56 (4-90)		0.209
Infiltrate area [‡]	28.2±24.51 (1.3-110.0)		45.5±50.83 (2.0-143.7)		0.540

[¶]5 patients with insufficient clinical follow-up are not shown in the table.
[§]Patients with isolates identified at the species level
[‡]Vision level could not be evaluated in 1 patient from each group.
[‡]Infiltrate area could not be measured in 2 patients.
SD: Standard deviation, min: Minimum, max: Maximum

The prevalence and predisposing factors of fungal keratitis vary with gender and age.^{4,11,15,16} In studies conducted in different regions of India, the highest prevalence was found in men 50-60 years of age.^{12,17,18} In developing countries, the prevalence was reported to be 2 to 5 times higher in men than in women,^{11,12} whereas Tanure et al.¹⁹ determined that the rates of men and women were similar among cases reported from North America.

In our study, male patients outnumbered females (36.8% females, 63.2% males) and the majority of cases (27/38, 71%) were over 40 years of age. Male predominance was more pronounced in patients under the age of 40 years (8/11; 72.7%), and consistent with this, trauma was the most common predisposing factor in this age group (7/11; 63.6%). In general, the 20-40 age range is most actively studied; therefore, the risk of trauma is highest among those working in agriculture and animal husbandry.¹¹ In this age group, men experience ocular trauma more frequently than women because they work more in jobs based on physical strength.¹¹ In our study, 13 (76.4%) of the 17 patients with a history of trauma were men.

In our patients over 40 years of age, the gender distribution was more balanced (40.7% females, 59.2% males) and the prevalence of trauma was lower (10/27; 37%). In this age group, local and systemic pathologies that impair ocular surface immunity were the leading predisposing factors (13/27; 48.1%). With older age, the body's immune resistance weakens, corneal epithelialization slows, and susceptibility to chronic ocular and systemic diseases increases.²⁰ All of these factors facilitate the development of fungal keratitis.

The species of fungus involved in fungal keratitis is closely associated with medical history and predisposing factors.⁴ Yeasts largely cause infection in patients with underlying ocular or systemic disease, while molds are often associated with ocular trauma.^{21,22} In this study, a history of trauma was present in 16 (47%) of 34 cases caused by molds but only 1 (25%) case caused by yeasts. All other cases involving yeasts were associated with chronic ocular surface disease, as well as a history of systemic disease in 2 patients (one with immunodeficiency secondary to a genetic syndrome and one with bullous pemphigoid).

Fungal keratitis pathogens may vary geographically depending on climate and environmental conditions.²³ Molds are the most common isolates in cases of microbial keratitis in studies conducted in many developing countries with tropical or subtropical climates.²⁴ Of these, *Aspergillus* species are more prevalent in subtropical regions, while *Fusarium* is more common in tropical regions.^{12,25,26,27,28} Binnani et al.¹⁵ reported that of 180 fungal isolates in their study, 63.3% were *Aspergillus* species and most of those (55%) were *Aspergillus fumigatus*. The authors stated that in regions where *Aspergillus* spores are concentrated in the air, contact with eyes that have an infectious disposition leads to infection.¹⁵ In our study, molds were the causative agent in 34 patients (89.4%). *Aspergillus* species (11/26, 42.3%) were the most commonly identified agents in

positive fungal cultures. *Aspergillus fumigatus* was the most frequently isolated species, detected in 4 patients. *Fusarium* species, detected in 8 patients (30.7%), were the second most frequently isolated agents in our study, similar to the results reported in many developing and hot climate countries.^{29,30} Yeasts, which are the predominant cause of fungal keratitis in temperate climates and developed countries, were identified in 4 patients (10.6%) in our study. Considering the socioeconomic level of the patients in our study, the geographic conditions of our region, and the high prevalence of trauma in our cases, this numerical distribution of fungal isolates can be considered an expected result.

Fungal keratitis is therapeutically challenging, and many studies have reported limited treatment success.^{17,18,31} In similar studies, nonresponse to medical treatment and the need for keratoplasty have been reported at rates of 40-47% in developing countries^{18,32} and 21-25% in developed countries.^{4,19,33,34} Nielsen et al.³ reported in their study that only 36% of patients could be successfully treated with medical therapies and 52% underwent keratoplasty. Similar to the rates reported in the literature, anatomic success was achieved with medical treatment and minor surgical interventions (AMT and corneal patch graft) in 50% of the patients in our study (19/38; treatment responders).

Resistance to many antifungal drugs among *Fusarium* species limits treatment success in *Fusarium* keratitis, both in terms of preserving anatomical integrity and vision level.^{35,36} Many studies have demonstrated the efficacy of topical natamycin and its superiority to voriconazole in *Fusarium* keratitis.^{37,38} Pérez-Balbuena et al.³⁵ reported that 14 (23%) of 61 *Fusarium* keratitis cases underwent tectonic PK and 14 (23%) underwent evisceration. The authors stated that evisceration was not needed in any of the patients treated with natamycin, and that other antifungal drugs were used in many cases due to the lack of access to natamycin in Mexico for a large part of the study period.³⁵ Walther et al.³⁶ reported that 9 (60%) of 15 *Fusarium* keratitis patients underwent keratoplasty and 3 (20%) underwent evisceration. The authors attributed this unfavorable clinical outcome with the absence of a commercially available natamycin product in Germany.³⁶

Although statistical significance could not be determined due to the small number of patients, the improvement rate was lower in *Fusarium* cases in our study compared to other fungal keratitis cases (Table 4). Only 2 (33.3%) of 6 *Fusarium* cases (2 patients were not included in the evaluation due to insufficient clinical follow-up) improved with medical treatment. This rate was 63.6% in *Aspergillus* cases and 66.6% in *Candida* cases (Table 4). Of the other *Fusarium* cases, 2 patients underwent PK and 2 underwent evisceration. In our study, clinical indicators of corneal infection severity at initial presentation did not differ according to the species of fungus involved. Therefore, the poor prognosis of *Fusarium* cases may be attributable to the multidrug resistance of this fungus against the antifungals

administered. The absence of natamycin as a commercial product in our country is an important barrier to the treatment of these challenging cases. On the other hand, systemic and topical posaconazole was shown to be effective in cases of *Fusarium* keratitis resistant to conventional antifungal therapies.^{39,40} The high lipophilicity of this drug increases its penetration into the ocular tissues and thus its efficacy.³⁹ Of the 4 patients with *Fusarium* keratitis who did not respond to conventional antifungal therapy, 2 patients were no longer eligible for medical treatment by the time *Fusarium* was identified, and 1 patient could not be treated with posaconazole because the drug could not be obtained at that time. Consequently, 2 of these 3 patients underwent evisceration.

The prevalence of polymicrobial infection in microbial keratitis has been reported in the range of 1.9-15.8%.^{41,42} It is noteworthy that in fungal keratitis, the reported range is wider and includes higher rates (5-60%).^{6,43,44} Fernandes et al.⁴³ reported the prevalence of polymicrobial infection as 36.1% in 94 fungal keratitis cases, while Ahn et al.⁶ reported this rate as 39.7% in their 7-year case series. In our study, polymicrobial etiology was present in 27 (41.5%) of 65 fungal keratitis cases over a 6-year period, consistent with the literature. Antibiosis and the ability to produce biofilm are properties of both molds and yeasts which are prominent features related to the bacterial-fungal interaction, although their role in polymicrobial infections has not been fully elucidated.^{45,46}

In our study, we found that central and large infiltrates were associated with treatment failure ($p=0.036$ and $p=0.049$, respectively). Different studies have shown that the presence of central infiltrate in infectious keratitis is associated with an increased need for PK.^{47,48} Prajna et al.⁴⁹ showed that in fungal keratitis, many parameters related to lesion characteristics at presentation, including infiltrate size and presence of a central lesion, were associated with the development of perforation, epithelialization time, post-treatment vision level, and scar size. Keay et al.⁴ reported that infiltrate size was associated with vision loss and the need for surgical intervention in cases of fungal keratitis in contact lens wearers. Lalitha et al.⁵⁰ stated that ulcers exceeding 14 mm² in size and the presence of hypopyon may be predictors of treatment failure. In infectious keratitis, a large infiltrate at presentation may be related to the patient presenting late, receiving inadequate treatment or not complying with treatment prescribed at another center, resistance of the pathogen to treatment, or the patient's immune status.⁴³ Although these factors often coexist and the main cause can be difficult to determine, understanding the relationship between infiltrate characteristics and treatment outcome can be important in terms of considering aggressive treatment options in cases presenting with large and central lesions and monitoring these patients more closely.

Study Limitations

Our study data were limited by the retrospective study design and the absence of information on epidemiological factors of fungal keratitis not included in the patients' medical records, such as socioeconomic status, occupation, and rural/urban residence.

Conclusion

Fungal keratitis is an important public health problem in our region, and ocular trauma is a major etiological factor in patients under 40 years of age. In our study, molds were the main pathogens of fungal keratitis in our region, with *Aspergillus* species being predominant. With intensive topical and systemic antifungal treatment and minor surgical interventions when necessary, this challenging infection can be treated without the need for emergency keratoplasty in the majority of cases. In cases presenting with large and central lesions, aggressive treatment options should be preferred and close follow-up is recommended.

Ethics

Ethics Committee Approval: Çukurova University Faculty of Medicine Non-Invasive Clinical Research Ethics Committee (date: 3 July 2020).

Informed Consent: Retrospective study.

Peer-review: Externally peer reviewed.

Authorship Contributions

Surgical and Medical Practices: M.Y., E.E., İ.İ.H., H.K., A.A., Concept: M.Y., M.İ., İ.İ.H., Design: M.Y., M.İ., İ.İ.H., Data Collection or Processing: N.G., A.İ., H.K., A.A., Analysis or Interpretation: İ.İ.H., E.E., M.Y., M.İ., Literature Search: İ.İ.H., M.İ., Writing: İ.İ.H., E.E., M.Y., M.İ., H.K.

Conflict of Interest: No conflict of interest was declared by the authors.

Financial Disclosure: The authors declared that this study received no financial support.

References

1. Sekeroglu HT, Yar K, Erdem E, Uguz A, Yagmur M, Ersoz C, Kibar F. Cytologically diagnosed fungal keratitis: clinical features and treatment results. *Turk J Ophthalmol.* 2010;40:255-260.
2. Rogers GM, Goins KM, Sutphin JE, Kitzmann AS, Wagoner MD. Outcomes of treatment of fungal keratitis at the University of Iowa Hospitals and Clinics: a 10-year retrospective analysis. *Cornea.* 2013;32:1131-1136.
3. Nielsen SE, Nielsen E, Julian HO, Lindegaard J, Højgaard K, Ivarsen A, Hjortdal J, Heegaard S. Incidence and clinical characteristics of fungal keratitis in a Danish population from 2000 to 2013. *Acta Ophthalmol.* 2015;93:54-58.
4. Keay LJ, Gower EW, Iovieno A, Oechsler RA, Alfonso EC, Matoba A, Colby K, Tuli SS, Hammersmith K, Cavanagh D, Lee SM, Irvine J, Stulting RD, Mauger TF, Schein OD. Clinical and microbiological characteristics of fungal keratitis in the United States, 2001-2007: a multicenter study. *Ophthalmology.* 2011;118:920-926.

5. Gaujoux T, Borsali E, Goldschmidt P, Chaumeil C, Baudouin C, Nordmann JP, Sahel JA, Laroche L, Borderie VM. Fungal keratitis in France. *Acta Ophthalmol.* 2011;89:e215-e216.
6. Ahn M, Yoon KC, Ryu SK, Cho NC, You IC. Clinical aspects and prognosis of mixed microbial (bacterial and fungal) keratitis. *Cornea.* 2011;30:409-413.
7. Samson RA, Visagie CM, Houbraken J, Hong SB, Hubka V, Klaassen CH, Perrone G, Seifert KA, Susca A, Tanney JB, Varga J, Kocsubé S, Szigeti G, Yaguchi T, Frisvad JC. Phylogeny, identification and nomenclature of the genus *Aspergillus*. *Stud Mycol.* 2014;78:141-173.
8. Homa M, Shobana CS, Singh YR, Manikandan P, Selvam KP, Kredics L, Narendran V, Vágvölgyi C, Galgóczy L. *Fusarium* keratitis in South India: causative agents, their antifungal susceptibilities and a rapid identification method for the *Fusarium solani* species complex. *Mycoses.* 2013;56:501-511.
9. Harbiyeli II, Oruz O, Erdem E, Cam B, Demirkazik M, Acikalin A, Kibar F, Ilkit M, Yarkin E, Yagmur M. Clinical aspects and prognosis of polymicrobial keratitis caused by different microbial combinations: a retrospective comparative case study. *Int Ophthalmol.* 2021;41:3849-3860.
10. Ghosh AK, Gupta A, Rudramurthy SM, Paul S, Hallur VK, Chakrabarti A. Fungal keratitis in North India: Spectrum of agents, risk factors and treatment. *Mycopathologia.* 2016;181:843-850.
11. Chowdhary A, Singh K. Spectrum of fungal keratitis in North India. *Cornea.* 2005;24:8-15.
12. Chander J, Sharma A. Prevalence of fungal corneal ulcers in northern India. *Infection.* 1994;22:207-209.
13. Yilmaz S, Ozturk I, Maden A. Microbial keratitis in West Anatolia, Turkey: a retrospective review. *Int Ophthalmol.* 2007;27:261-268.
14. Hilmioglu-Polar S, Seyedmousavi S, Ilkit M, Hedayati MT, Inci R, Tumbay E, Denning DW. Estimated burden of serious human fungal diseases in Turkey. *Mycoses.* 2019;62:22-31.
15. Binnani A, Gupta PS, Gupta A. Epidemio-clinico-microbiological study of mycotic keratitis in north-west region of Rajasthan. *Mycopathologia.* 2018;183:717-722.
16. Bharathi MJ, Ramakrishnan R, Vasu S, Meenakshi R, Palaniappan R. Epidemiological characteristics and laboratory diagnosis of fungal keratitis. A three-year study. *Indian J Ophthalmol.* 2003;51:315-321.
17. Rautaraya B, Sharma S, Kar S, Das S, Sahu SK. Diagnosis and treatment outcome of mycotic keratitis at a tertiary eye care center in eastern India. *BMC Ophthalmol.* 2011;11:39.
18. Saha S, Banerjee D, Khetan A, Sengupta J. Epidemiological profile of fungal keratitis in urban population of West Bengal, India. *Oman J Ophthalmol.* 2009;2:114-118.
19. Tanure MA, Cohen EJ, Sudesh S, Rapuano CJ, Laibson PR. Spectrum of fungal keratitis at Wills Eye Hospital, Philadelphia, Pennsylvania. *Cornea.* 2000;19:307-312.
20. Rhim JH, Kim JH, Yeo EJ, Kim JC, Park SC. Caveolin-1 as a novel indicator of wound-healing capacity in aged human corneal epithelium. *Mol Med.* 2010;16:527-534.
21. Sun RL, Jones DB, Wilhelmus KR. Clinical characteristics and outcome of *Candida* keratitis. *Am J Ophthalmol.* 2007;143:1043-1045.
22. Tuft SJ, Tullo AB. Fungal keratitis in the United Kingdom 2003-2005. *Eye (Lond).* 2009;23:1308-1313.
23. Bharathi MJ, Ramakrishnan R, Meenakshi R, Padmavathy S, Shivakumar C, Srinivasan M. Microbial keratitis in South India: influence of risk factors, climate, and geographical variation. *Ophthalmic Epidemiol.* 2007;14:61-69.
24. Rondeau N, Bourcier T, Chaumeil C, Borderie V, Touzeau O, Scat Y, Thomas F, Baudouin C, Nordmann JP, Laroche L. Les kératomycoses au Centre Hospitalier National d'Ophthalmologie des Quinze-Vingts [Fungal keratitis at the Centre Hospitalier National d'Ophthalmologie des Quinze-Vingts: retrospective study of 19 cases]. *J Fr Ophthalmol.* 2002;25:890-896.
25. Upadhyay MP, Karmacharya PC, Koirala S, Shah DN, Shakya S, Shrestha JK, Bajracharya H, Gurung CK, Whitcher JP. The Bhaktapur eye study: ocular trauma and antibiotic prophylaxis for the prevention of corneal ulceration in Nepal. *Br J Ophthalmol.* 2001;85:388-392.
26. Houang E, Lam D, Fan D, Seal D. Microbial keratitis in Hong Kong: relationship to climate, environment and contact-lens disinfection. *Trans R Soc Trop Med Hyg.* 2001;95:361-367.
27. Panda A, Sharma N, Das G, Kumar N, Satpathy G. Mycotic keratitis in children: epidemiologic and microbiologic evaluation. *Cornea.* 1997;16:295-299.
28. Srinivasan R, Kanungo R, Goyal JL. Spectrum of oculomycosis in South India. *Acta Ophthalmol (Copenh).* 1991;69:744-749.
29. Upadhyay MP, Karmacharya PC, Koirala S, Tuladhar NR, Bryan LE, Smolin G, Whitcher JP. Epidemiologic characteristics, predisposing factors, and etiologic diagnosis of corneal ulceration in Nepal. *Am J Ophthalmol.* 1991;111:92-99.
30. Xie L, Dong X, Shi W. Treatment of fungal keratitis by penetrating keratoplasty. *Br J Ophthalmol.* 2001;85:1070-1074.
31. Gopinathan U, Sharma S, Garg P, Rao GN. Review of epidemiological features, microbiological diagnosis and treatment outcome of microbial keratitis: experience of over a decade. *Indian J Ophthalmol.* 2009;57:273-279.
32. Pradhan L, Sharma S, Nalamada S, Sahu SK, Das S, Garg P. Natamycin in the treatment of keratomycosis: correlation of treatment outcome and in vitro susceptibility of fungal isolates. *Indian J Ophthalmol.* 2011;59:512-514.
33. Iyer SA, Tuli SS, Wagoner RC. Fungal keratitis: emerging trends and treatment outcomes. *Eye Contact Lens.* 2006;32:267-271.
34. Ritterband DC, Seedor JA, Shah MK, Koplin RS, McCormick SA. Fungal keratitis at the New York eye and ear infirmary. *Cornea.* 2006;25:264-267.
35. Pérez-Balbuena AL, Vanzzini-Rosano V, Valadéz-Virgen Jde J, Campos-Möller X. *Fusarium* keratitis in Mexico. *Cornea.* 2009;28:626-630.
36. Walther G, Stasch S, Kaerger K, Hamprecht A, Roth M, Cornely OA, Geerling G, Mackenzie CR, Kurzai O, von Lilienfeld-Toal M. *Fusarium* Keratitis in Germany. *J Clin Microbiol.* 2017;55:2983-2995.
37. Prajna NV, Krishnan T, Mascarenhas J, Rajaraman R, Prajna L, Srinivasan M, Raghavan A, Oldenburg CE, Ray KJ, Zegans ME, McLeod SD, Porco TC, Acharya NR, Lietman TM. The mycotic ulcer treatment trial: A randomized trial comparing natamycin vs voriconazole. *JAMA Ophthalmol.* 2013;131:422-429.
38. Sharma S, Das S, Viridi A, Fernandes M, Sahu SK, Kumar Koday N, Ali MH, Garg P, Motukupally SR. Re-appraisal of topical 1% voriconazole and 5% natamycin in the treatment of fungal keratitis in a randomised trial. *Br J Ophthalmol.* 2015;99:1190-1195.
39. Sponzel WE, Graybill JR, Nevarez HL, Dang D. Ocular and systemic posaconazole (SCH-56592) treatment of invasive *Fusarium solani* keratitis and endophthalmitis. *Br J Ophthalmol.* 2002;86:829-830.
40. Altun A, Kurna SA, Sengor T, Altun G, Olcaysu OO, Aki SF, Simsek MH. Effectiveness of posaconazole in recalcitrant fungal keratitis resistant to conventional antifungal drugs. *Case Rep Ophthalmol Med.* 2014;2014:701653.
41. Ni N, Nam EM, Hammersmith KM, Nagra PK, Azari AA, Leiby BE, Dai Y, Cabrera FA, Ma JF, Lambert CE Jr, Honig SE, Rapuano CJ. Seasonal, geographic, and antimicrobial resistance patterns in microbial keratitis: 4-year experience in eastern Pennsylvania. *Cornea.* 2015;34:296-302.
42. Kalamurthy J, Kalavathy CM, Parmar P, Nelson Jesudasan CA, Thomas PA. Spectrum of bacterial keratitis at a tertiary eye care centre in India. *Biomed Res Int.* 2013;2013:181564.
43. Fernandes M, Vira D, Dey M, Tanzin T, Kumar N, Sharma S. Comparison between polymicrobial and fungal keratitis: Clinical features, risk factors, and outcome. *Am J Ophthalmol.* 2015;160:873-881.e2.
44. Pate JC, Jones DB, Wilhelmus KR. Prevalence and spectrum of bacterial co-infection during fungal keratitis. *Br J Ophthalmol.* 2006;90:289-292.
45. Costa-Orlandi CB, Sardi JCO, Pitanguí NS, de Oliveira HC, Scorzoni L, Galeane MC, Medina-Alarcón KP, Melo WCMA, Marcelino MY, Braz

- JD, Fusco-Almeida AM, Mendes-Giannini MJS. Fungal biofilms and polymicrobial diseases. *J Fungi (Basel)*. 2017;3:22.
46. Ponce-Angulo DG, Bautista-Hernández LA, Calvillo-Medina RP, Castro-Tecorral FI, Aparicio-Ozores G, López-Villegas EO, Ribas-Aparicio RM, Bautista-de Lucio VM. Microscopic characterization of biofilm in mixed keratitis in a novel murine model. *Microb Pathog*. 2020;140:103953.
47. McLeod SD, LaBree LD, Tayyanipour R, Flowers CW, Lee PP, McDonnell PJ. The importance of initial management in the treatment of severe infectious corneal ulcers. *Ophthalmology*. 1995;102:1943-1948.
48. Miedziak AI, Miller MR, Rapuano CJ, Laibson PR, Cohen EJ. Risk factors in microbial keratitis leading to penetrating keratoplasty. *Ophthalmology*. 1999;106:1166-1171.
49. Prajna NV, Krishnan T, Mascarenhas J, Srinivasan M, Oldenburg CE, Toutain-Kidd CM, Sy A, McLeod SD, Zegans ME, Acharya NR, Lietman TM, Porco TC. Predictors of outcome in fungal keratitis. *Eye (Lond)*. 2012;26:1226-1231.
50. Lalitha P, Prajna NV, Kabra A, Mahadevan K, Srinivasan M. Risk factors for treatment outcome in fungal keratitis. *Ophthalmology*. 2006;113:526-530.