



Palliative Efficacy of Intrastromal Amniotic Membrane Procedure in Symptomatic Bullous Keratopathy Patients

Onur Furundaoturan, Melis Palamar, Özlem Barut Selver

Ege University Faculty of Medicine, Department of Ophthalmology, İzmir, Turkey

Abstract

Objectives: To evaluate the palliative efficacy of the intrastromal human amniotic membrane (hAM) surgery technique in patients with symptomatic bullous keratopathy and limited visual potential.

Materials and Methods: The study was carried out retrospectively by reviewing the medical data of 10 patients with poor visual prognosis who underwent intrastromal hAM surgery due to bullous keratopathy-related severe pain. Visual acuity, surgical indication, epithelization time, preoperative and postoperative pain scores, as well as anterior segment optical coherence tomography images and anterior segment photographs were obtained from the medical records.

Results: Ten patients (6 females/4 males) were included in the study. Nine patients underwent surgery for pseudophakic bullous keratopathy and glaucoma, and 1 patient due to graft failure and glaucoma. The mean time for corneal epithelization was 27.10 ± 13.05 days (range, 10-50), while the mean follow-up time was 37.5 ± 1.6 months (range, 36-39.2). Subjective pain score improved in all patients after surgery. Suture-induced keratitis occurred during follow-up in one patient and was controlled with medical treatment.

Conclusion: Intrastromal amniotic membrane surgery may be an alternative to keratoplasty for pain palliation in patients with limited visual prognosis after corneal transplantation when donor tissue is scarce. With this method, hAM remains on the ocular surface longer, and superficial stromal excision is believed to provide a more regular ocular surface and extend the asymptomatic period.

Keywords: Amniotic membrane inlay technique, bullous keratopathy, poor visual prognosis

Address for Correspondence: Özlem Barut Selver, Ege University Faculty of Medicine, Department of Ophthalmology, İzmir, Turkey

E-mail: ozleambarutselver@gmail.com **ORCID-ID:** orcid.org/0000-0003-3333-3349

Received: 06.04.2021 **Accepted:** 22.06.2021

Cite this article as: Furundaoturan O, Palamar M, Barut Selver Ö. Palliative Efficacy of Intrastromal Amniotic Membrane Procedure in Symptomatic Bullous Keratopathy Patients. Turk J Ophthalmol 2022;52:162-167

©Copyright 2022 by Turkish Ophthalmological Association
Turkish Journal of Ophthalmology, published by Galenos Publishing House.

Introduction

Bullous keratopathy (BK) is characterized by chronic edema and visual impairment due to corneal endothelial insufficiency. It often occurs after Fuchs endothelial dystrophy or endothelial trauma secondary to intraocular surgery and can cause severe pain.^{1,2,3} Keratoplasty is the primary treatment for eyes with visual potential.^{4,5} Palliative treatment methods are important for eyes without visual potential, especially in the management of pain. These methods include noninterventional approaches such as bandage contact lens use,⁶ as well as surgical options such as phototherapeutic keratectomy,⁷ cross-linking,⁸ stromal micropunctures,⁹ and conjunctival flaps.⁹

The human amniotic membrane (hAM) is the inner layer of the placenta consisting of the epithelium, basement membrane, and connective tissue. It has been used for years as a biomaterial in ocular surface diseases, including BK. hAM is used in BK for pain palliation and the treatment of recurrent epithelial erosion. It is usually applied to the ocular surface by direct suturing with the epithelial surface facing up. The hAM remains on the ocular surface for 2-8 weeks depending on the degree of inflammation present.^{2,10,11} Various modifications to the hAM transplantation procedure can be made if epithelial healing is not achieved or longer-term symptom control is needed. One of these is the inlay technique, in which the amniotic membrane is applied intra- or suprastomally.¹²

The aim of this study was to evaluate the clinical outcomes of the intrastromal hAM surgical technique performed for palliation of symptomatic BK in patients with limited visual potential.

Materials and Methods

The study was conducted by retrospectively screening the results of intrastromal amniotic membrane surgery for severe pain in 10 patients with BK and limited visual prognosis who were followed up in the Corneal Unit of the Ege University Faculty of Medicine.

The study was carried out in accordance with the principles of the Declaration of Helsinki after obtaining approval from the local medical research ethics committee and informed consent from each patient.

Visual acuity, surgical indication, epithelialization time, preoperative and postoperative pain scores (rated on scale of 0-10 with 0 being mildest and 10 most severe), anterior segment optical coherence tomography images, and anterior segment photographs were collected from the patients' records.

The intrastromal hAM surgical technique was performed as follows: After mechanical debridement of the corneal epithelium, a depth of approximately 100 μm was determined using an 8-mm trepan and superficial lamellar stromal dissection was performed in the central 8-mm area. A 360-degree peripheral corneal tunnel was then prepared using a crescent blade. Cryopreserved hAM cut using a 9-mm donor punch was obtained from the eye bank and prepared as described in the literature.¹³ It was then used to cover the dissection area with the epithelial side up and its peripheral ends placed in the prepared tunnel. The hAM was fixed in place with 8 interrupted nylon sutures in the peripheral cornea (Figure 1a-h).

Statistical Analysis

IBM SPSS Statistics version 20.0 software package (IBM Corp, Armonk, NY, USA) was used for statistical data analysis.

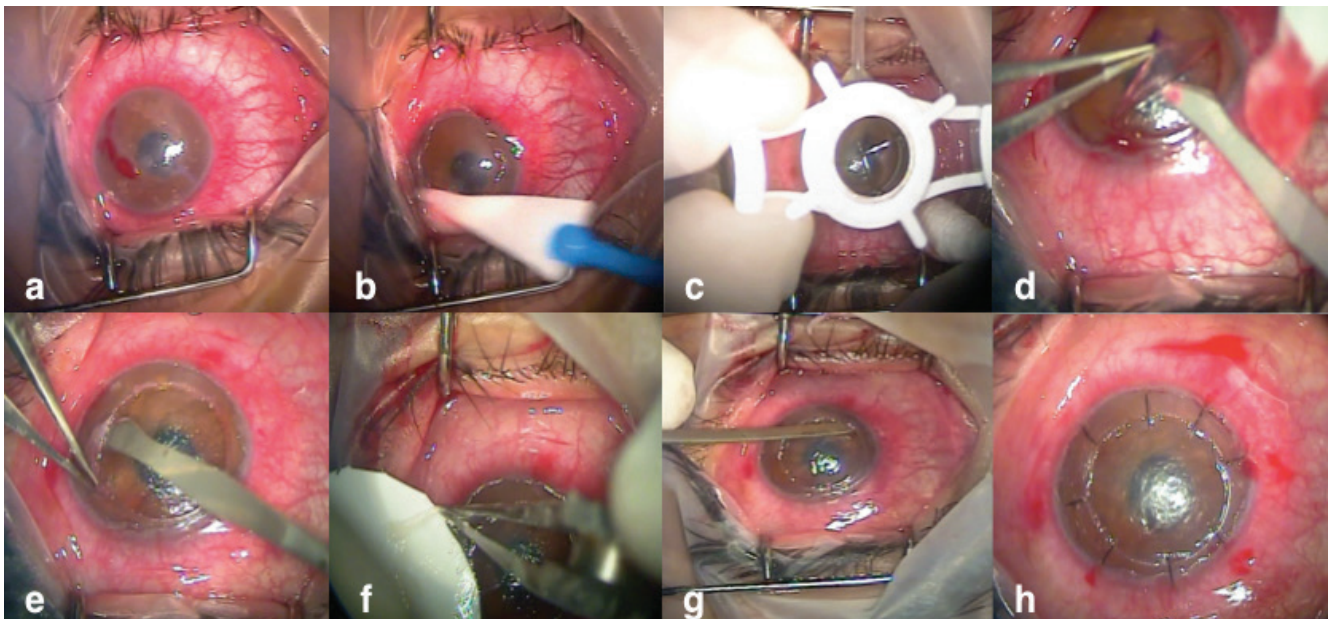


Figure 1. Steps of amniotic membrane implantation: a-b) Epithelial debridement, c) A 8-mm trepan is used to determine a depth of approximately 100 μm , d) Superficial lamellar stromal dissection, e) A 360-degree peripheral corneal tunnel is prepared using a crescent knife, f-g) The amniotic membrane is used to cover the defect epithelial side up, with peripheral ends placed into the prepared tunnel, h) The amniotic membrane is fixed to the peripheral cornea with 8 nylon interrupted sutures

Numerical variables were presented as mean, standard deviation, and range. Dependent data were evaluated using Mann-Whitney U test, with p values less than 0.05 were considered statistically significant.

Results

The mean age of the 10 patients (6 women, 4 men) was 68.5±15.6 years (range, 34-85). Surgical indications were pseudophakic BK and glaucoma in 9 patients and graft failure and glaucoma in 1 patient (Table 1). All of the patients included were symptomatic and had not benefited from previous conservative treatments (artificial tears, bandage contact lens). The mean time required for corneal epithelialization was 27.10±13.05 days (range, 10-50) (Figure 2a-h).

Preoperative visual acuity was counting fingers at 50 centimeters in 9 patients and counting fingers at 2 meters in 1 patient. Mean follow-up time was 37.5±1.6 months (range, 36-39.2). In all patients, the hAM remained visible between the epithelium and stroma and maintained its barrier function throughout follow-up, despite peripheral areas of partial degradation (Figure 3a-d, pre- and postoperative images of patient 4). Subjective pain score improved in all patients after surgery (preoperative mean 8.7 [range, 8-10]; postoperative mean 1.1 [range, 0-2]; p=0.00018). One patient developed keratitis with hypopyon associated with loose suture at 6-month follow-up that was controlled with appropriate antibiotherapy after removing the loose suture. No growth was detected in the microbiological sample obtained (Figure 4a-f).

Discussion

BK is characterized by chronic corneal edema and subepithelial bullous changes resulting from corneal endothelial insufficiency. Despite all of the advances in surgical methods, it remains a serious complication.¹⁴ The intrastromal hAM

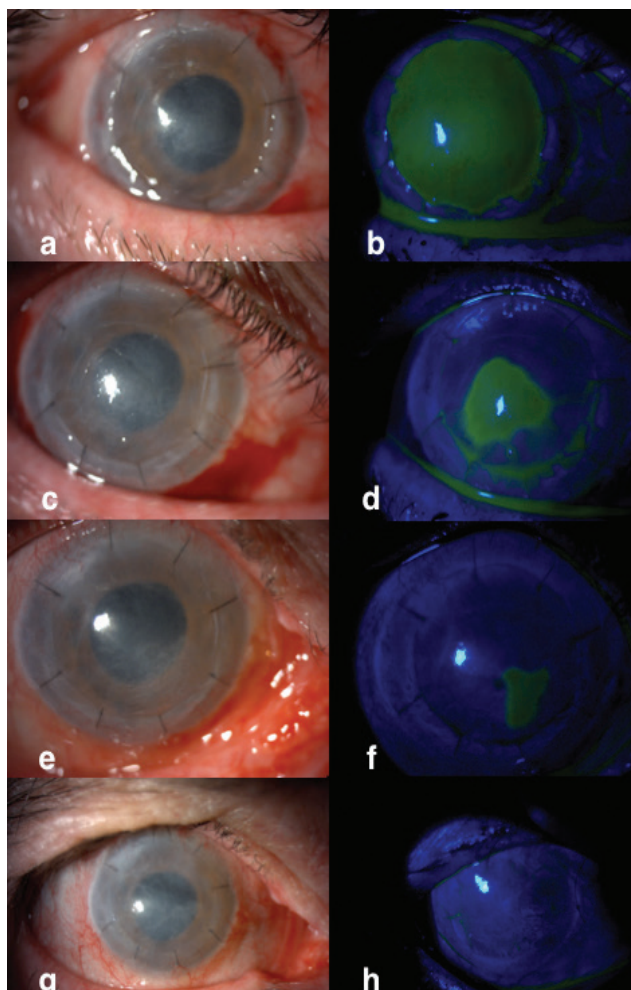


Figure 2. The corneal epithelialization process recorded using biomicroscopic photography during postoperative follow-up (a-h)

Table 1. Demographic characteristics, surgical indications, and examination findings of all patients (subjective pain scoring from a minimum of 1 to maximum of 10)

	Indication	Age (years)	Sex	Visual acuity	Follow-up time	Epithelialization time	Other characteristics	Subjective pain score	
								Before	After
Patient 1	BK	53	F	LP	39.0 months	50 days	Glaucoma	8	0
Patient 2	BK	85	F	NLP	36.0 months	18 days	Glaucoma, Keratitis	9	2
Patient 3	BK	77	F	HM	37.1 months	32 days	Glaucoma	8	1
Patient 4	Graft failure	71	F	CF 2 m	38.7 months	12 days	Glaucoma	8	1
Patient 5	BK	67	M	CF 20 cm	39.2 months	20 days	Glaucoma	9	2
Patient 6	BK	34	F	HM	38.7 months	28 days	Glaucoma	9	1
Patient 7	BK	62	M	CF 50 cm	38.2 months	23 days	Glaucoma	10	1
Patient 8	BK	85	M	HM	34.1 months	35 days	Glaucoma	9	0
Patient 9	BK	74	F	NLP	36.2 months	43 days	Glaucoma	8	2
Patient 10	BK	77	M	HM	38.2 months	10 days	Glaucoma	9	1

BK: Bullous keratopathy, M: Male, F: Female, LP: Light perception, NLP: No light perception, HM: Hand movements, CF: Counting fingers

technique is one of the treatment alternatives for symptomatic BK cases with limited visual potential.¹² With this procedure, hAM acts as a barrier for the corneal epithelium and effectively prevents corneal edema associated with endothelial failure from causing ocular surface disease.^{12,15} In this technique, hAM prepared to the size of the damaged area acts as a basement membrane for corneal epithelial cell proliferation and suppresses subsequent inflammation by reducing contact with tear-induced mediators.¹⁶

In the literature, there are studies reporting the use of hAM in patients with persistent epithelial defects and in patients with poor visual prognosis, and the patients' symptoms were reported to resolve with no recurrence.^{2,12,17} hAM is generally fixed to the ocular surface by various suturing methods. The most common is referred to as the "overlay" method, in which the graft is applied epithelial side up covering the entire epithelial defect and even the corneal surface. In this method, which protects the damaged area from external contact such as from a contact lens, the hAM is resorbed over 2-8 weeks depending on ocular surface inflammation.² However, this widely used method provides limited palliation in pathologies accompanied by chronic processes because of the epithelialization time, the occasional need to repeat the procedure, and the limited duration on the ocular surface.¹⁶ Placing a defect-sized hAM graft supracorally/intrastromally so as to trap it under the developing epithelial layer is referred to as the "inlay" technique. This method is proposed to enable the formation of an uninterrupted and smooth transition surface for epithelial cell growth. In addition, because the hAM remains under the epithelium, it is protected from enzymatic degradation and

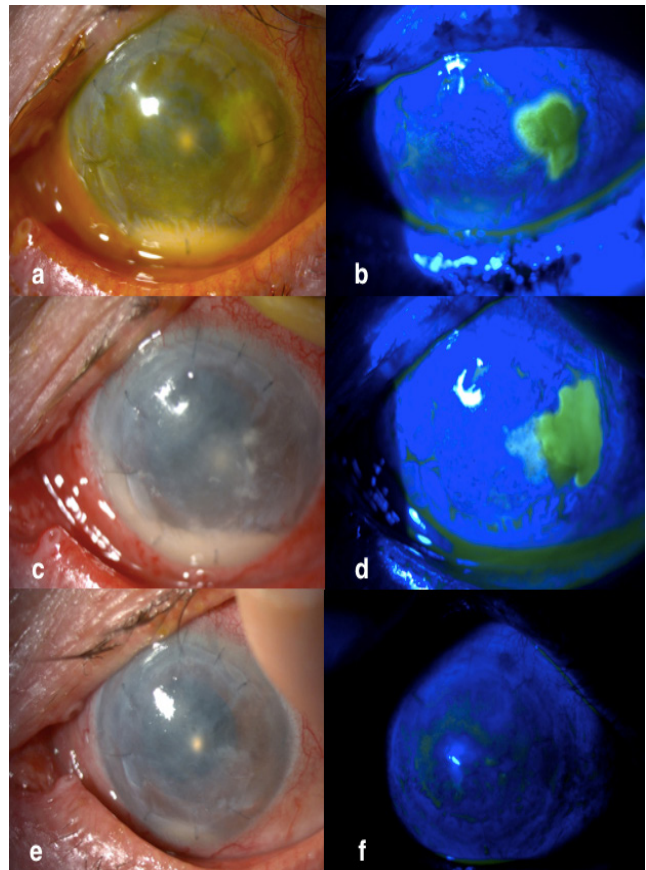


Figure 4. Anterior segment image and post-treatment status of the patient with hypopyon keratitis (a-f)

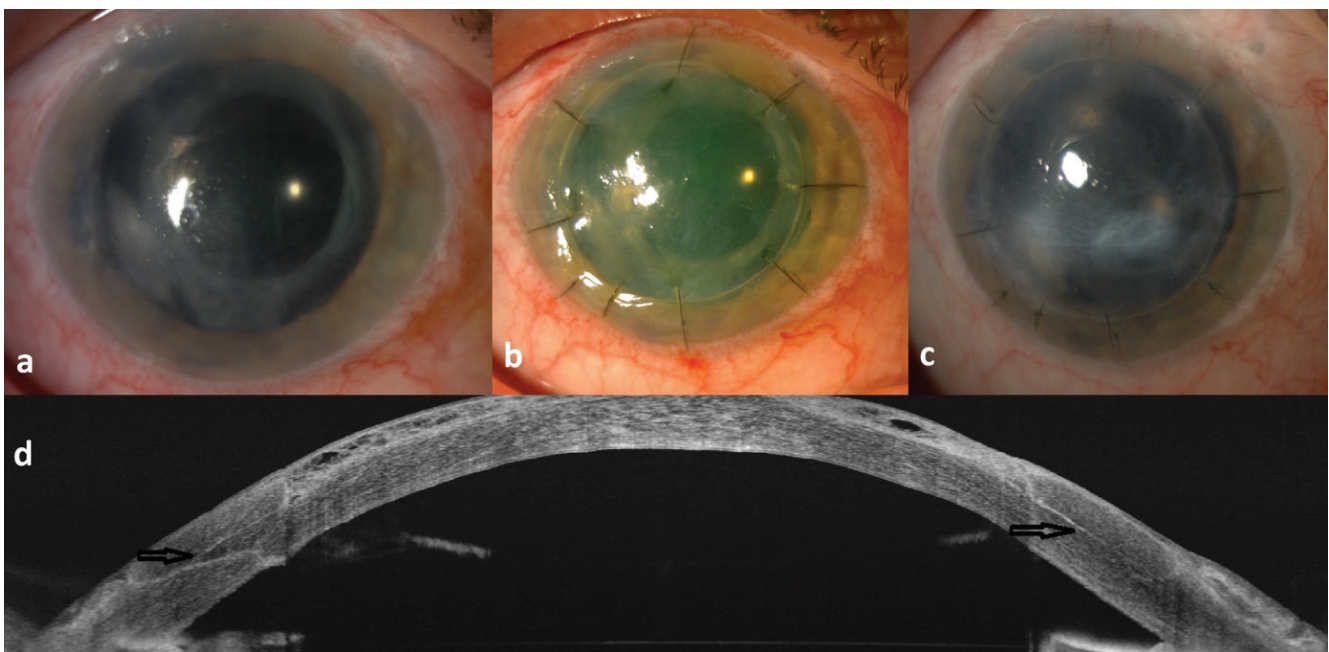


Figure 3. Images of patient 4: a) Anterior segment photograph before surgery, b) Anterior segment photograph at postoperative 3 months, c) Last follow-up photograph at postoperative 38 months, d) Anterior segment optical coherence tomography image at postoperative 36 months (amniotic membrane in the corneal peripheral tunnel is marked with black arrows)

remains in place long term. The greatest unwanted effect of this is visual impairment and unsatisfactory cosmetic appearance due to the semi-opaque nature of the amniotic membrane.^{17,18}

In a study from Turkey comparing overlay hAM suturing with an inlay method involving mechanical removal of the epithelium without stromal debridement and suturing the hAM into stromal pockets, it was observed that the inlay method provided pain palliation in more patients, better pain scores during follow-up, and significantly longer duration of the hAM on the ocular surface. There was no decline in pain palliation and pain scores in the inlay group, whereas the number of symptomatic patients in the overlay group increased during follow-up.¹⁸ In a case series by Espana et al.,¹⁷ one of the first studies in the literature to include the inlay technique, hAM was sutured to the prepared peripheral 360° stromal tunnel after only epithelial debridement. Pain palliation and reepithelialization were achieved in nearly all patients. In this study, approximately 100 µm of anterior stroma was removed during debridement in addition to the epithelium to prepare the bed for hAM.¹⁹ Removal of the superficial stroma by this method offers a smoother surface to receive the hAM and eliminates potential bulging caused by the thickness of hAM itself. Based on our review of the literature, we believe this modified inlay technique incorporating stromal excision is novel.

In studies in the literature reporting the use of hAM for palliation, indications have included causes such as pseudophakia, aphakia, and graft failure.^{2,12,17} Similarly, in this study pseudophakia was the indication in 9 patients and graft failure in 1 patient. All patients in our study also had glaucoma as a concomitant ocular pathology, which is the biggest difference between the current series and study groups in the literature. In previous studies using hAM methods, epithelialization rates were between 55% and 100%, with an average epithelialization time of 15.4-16.8 days.^{17,20,21} In the present study, reepithelialization was achieved in all patients (100%) and the mean epithelialization time was 27.10±13.05 days (range, 10-50), which is long compared to previous studies. As all patients in this study had a history of using antiglaucoma drops with epithelial toxicity, a relative delay in epithelial healing was considered an expected outcome.

Study Limitations

In the literature, pain palliation after hAM surgery has been reported at rates varying between 22% and 90%.^{17,20,21} In our study, the rate of successful pain palliation was 100%, with statistically significant pain control in all patients. Here again, we believe that stromal excision to a depth corresponding to the thickness of the amniotic membrane graft may result in more effective pain palliation by providing a more regular ocular surface.

In the few studies in the literature reporting inlay surgical techniques, the mean follow-up period was 7 months. The follow-up time in the current study was 37.5±1.6 months (range, 36-39.2), which is quite long compared to the literature. Consistent with the literature, our study showed that hAM placed

between the corneal stroma and newly forming epithelium could remain on the ocular surface longer.^{17,18}

Conclusion

In conclusion, the intrastromal amniotic membrane inlay technique should be kept in mind as an alternative to corneal transplantation and an auxiliary method for pain palliation in BK patients with poor visual prognosis and little cosmetic concern. Moreover, the method of removing the superficial stroma creates a more regular ocular surface and may provide stability over long-term follow-up.

Ethics

Ethics Committee Approval: Ege University Medical Research Ethics Committee (decision no: 21-3.1T/54, 18.03.21).

Informed Consent: Obtained.

Peer-review: Externally peer reviewed.

Authorship Contributions

Surgical and Medical Practices: Ö.B.S., M.P., Concept: Ö.B.S., M.P., Design: Ö.B.S., M.P., Data Collection or Processing: O.F., Ö.B.S., Analysis or Interpretation: O.F., Ö.B.S., M.P., Literature Search: O.F., Ö.B.S., Writing: O.F., Ö.B.S.

Conflict of Interest: No conflict of interest was declared by the authors.

Financial Disclosure: The authors declared that this study received no financial support.

References

1. Aquavella JV. Chronic corneal edema. *Am J Ophthalmol.* 1973;76:201-207.
2. Pires RT, Tseng SC, Prabhasawat P, Puangsricharem V, Maskin SL, Kim JC, Tan DT. Amniotic membrane transplantation for symptomatic bullous keratopathy. *Arch Ophthalmol.* 1999;117:1291-1297.
3. Palamar M, Kiyat P, Yagci A. Dry eye and meibomian gland dysfunction in pseudophakic bullous keratopathy. *Int Ophthalmol.* 2019;39:393-396.
4. Brady SE, Rapuano CJ, Arentsen JJ, Cohen EJ, Laibson PR. Clinical indications for and procedures associated with penetrating keratoplasty, 1983-1988. *Am J Ophthalmol.* 1989;108:118-122.
5. Barut Selver O, Karaca I, Palamar M, Egrilmez S, Yagci A. Graft Failure and Repeat Penetrating Keratoplasty. *Exp Clin Transplant.* 2021;19:72-76.
6. Gasset AR, Kaufman HE. Bandage Lenses in the Treatment of Bullous Keratopathy. *Am J Ophthalmol.* 1971;72:376-380.
7. Maini R, Sullivan L, Snibson GR, Taylor HR, Loughnan MS. A comparison of different depth ablations in the treatment of painful bullous keratopathy with phototherapeutic keratectomy. *Br J Ophthalmol.* 2001;85:912-915.
8. Kaya E, Egrilmez S, Palamar M. Effect of Corneal Collagen Cross-Linking on Quality of Life in Patients with Bullous Keratopathy. *Turkiye Klinikleri J Ophthalmol.* 2015;24:95-101.
9. Cormier G, Brunette I, Boisjoly HM, LeFrançois M, Shi ZH, Guertin MC. Anterior stromal punctures for bullous keratopathy. *Arch Ophthalmol.* 1996;114:654-658.
10. Palamar M, Kaya E, Egrilmez S, Akalin T, Yagci A. Amniotic membrane transplantation in surgical management of ocular surface squamous neoplasias: long-term results. *Eye (Lond).* 2014;28:1131-1135.
11. Palamar Onay M, Yaman B, Akalin T, Yağcı A. Amniotic Membrane Transplantation in Surgical Treatment of Conjunctival Melanoma: Long-term Results. *Turk J Ophthalmol.* 2017;48:15-18.
12. Siu GD, Young AL, Cheng LL. Long-term symptomatic relief of bullous keratopathy with amniotic membrane transplant. *Int Ophthalmol.* 2015;35:777-783.

13. Kim JC, Tseng SC. Transplantation of preserved human amniotic membrane for surface reconstruction in severely damaged rabbit corneas. *Cornea*. 1995;14:473-484.
14. Pricopie S, Istrate S, Voinea L, Leasu C, Paun V, Radu C. Pseudophakic bullous keratopathy. *Rom J Ophthalmol*. 2017;61:90-94.
15. Koizumi N, Fullwood NJ, Bairaktaris G, Inatomi T, Kinoshita S, Quantock AJ. Cultivation of Corneal Epithelial Cells on Intact and Denuded Human Amniotic Membrane. *Invest Ophthalmol Vis Sci*. 2000;41:2506-2513.
16. Letko E, Stechschulte SU, Kenyon KR, Sadeq N, Romero TR, Samson CM, Nguyen QD, Harper SL, Primack JD, Azar DT, Grueterich M, Dohlman CH, Baltatzis S, Foster CS. Amniotic membrane inlay and overlay grafting for corneal epithelial defects and stromal ulcers. *Arch Ophthalmol*. 2001;119:659-663.
17. Espana EM, Grueterich M, Sandoval H, Solomon A, Alfonso E, Karp CL, Fantes F, Tseng SC. Amniotic membrane transplantation for bullous keratopathy in eyes with poor visual potential. *J Cataract Refract Surg*. 2003;29:279-284.
18. Altiparmak UE, Oflu Y, Yildiz EH, Budak K, Aslan BS, Nurozler A, Onat M, Kasim R, Duman S. Prospective comparison of two suturing techniques of amniotic membrane transplantation for symptomatic bullous keratopathy. *Am J Ophthalmol*. 2009;147:442-446.
19. Tanaka TS, Demirci H. Cryopreserved Ultra-Thick Human Amniotic Membrane for Conjunctival Surface Reconstruction After Excision of Conjunctival Tumors. *Cornea*. 2016;35:445-450.
20. Mejía LE, Santamaría JP, Acosta C. Symptomatic management of postoperative bullous keratopathy with nonpreserved human amniotic membrane. *Cornea*. 2002;21:342-345.
21. Georgiadiş NS, Ziakas NG, Boboridis KG, Terzidou C, Mikropoulos DG. Cryopreserved amniotic membrane transplantation for the management of symptomatic bullous keratopathy. *Clin Exp Ophthalmol*. 2008;36:130-135.