



# Hedgehog Signal Defect Leading to Familial Exudative Vitreoretinopathy-Like Disease and Gastrointestinal Malformation

© Nedime Şahinoğlu Keşkek\*, © İmren Akkoyun\*\*, © Abdülkerim Temiz\*\*\*, © Özgür Kütük\*\*\*\*

\*Başkent University Faculty of Medicine, Adana Research and Training Center, Department of Ophthalmology, Adana, Turkey

\*\*Başkent University Faculty of Medicine, Department of Ophthalmology, Ankara, Turkey

\*\*\*Başkent University Faculty of Medicine, Adana Research and Training Center, Department of Pediatric Surgery, Adana, Turkey

\*\*\*\*Başkent University Faculty of Medicine, Adana Research and Training Center, Department of Medical Genetics, Adana, Turkey

## Abstract

**Objectives:** The aim of the study was to present a new genetic association presenting with gastrointestinal tract malformations (GTMs) and familial exudative vitreoretinopathy (FEVR)-like disease and review the genetics of Hedgehog signaling.

**Materials and Methods:** Three neonates were diagnosed with FEVR-like retinal vascular disease upon routine ophthalmological examination during hospitalization in the neonatal surgical intensive care unit for GTMs. Genetic analysis of the neonates was performed.

**Results:** Gestational age of the neonates was 39, 38, and 39 weeks and birth weights were 3,500, 3,600, and 3,300 grams, respectively. All six eyes of the three infants were treated by laser photocoagulation. Recurrence was not seen in any of the eyes. Genetical analysis of all the neonates diagnosed with FEVR-like disease revealed defects in the Hedgehog pathway.

**Conclusion:** FEVR is a genetically well-defined retinal vascular disease. The current study is the first to show an association between FEVR-like retinal vascular disease and GTMs. This study demonstrates the importance of the Hedgehog pathway in retinal vascular and gut development.

**Keywords:** Familial exudative vitreoretinopathy, gastrointestinal tract malformations, genetic, hedgehog pathway, retinal vascular disease

**Address for Correspondence:** Nedime Şahinoğlu Keşkek, Başkent University Faculty of Medicine, Adana Research and Training Center, Department of Ophthalmology, Adana, Turkey

E-mail: nedime\_sahin@yahoo.com **ORCID-ID:** orcid.org/0000-0001-8544-103X

**Received:** 07.01.2021 **Accepted:** 22.06.2021

**Cite this article as:** Şahinoğlu Keşkek N, Akkoyun İ, Temiz A, Kütük Ö. Hedgehog Signal Defect Leading to Familial Exudative Vitreoretinopathy-Like Disease and Gastrointestinal Malformation. Turk J Ophthalmol 2022;52:174-178

©Copyright 2022 by Turkish Ophthalmological Association  
Turkish Journal of Ophthalmology, published by Galenos Publishing House.

## Introduction

Familial exudative vitreoretinopathy (FEVR) is a congenital retinal vascular disease characterized by retinal nonperfusion, proliferative retinopathy, and retinal detachment.<sup>1</sup> Clinically, FEVR displays remarkably varying phenotypes, from barely detectable retinal vascular anomaly to retinal detachment.<sup>2</sup> Classical clinical findings consist of peripheral avascular retina, neovascularization, exudation, dragging of vascular elements, and retinal detachment.<sup>1</sup> Mutations of the Wnt/Norrin signaling pathway underlie the molecular mechanisms leading to FEVR.<sup>3</sup> Particularly, four genes are well documented to be related to FEVR: *FZD4*, *LRP5*, *TSPAN12*, and *NDP*.<sup>3,4,5,6</sup>

Hedgehog (Hh) signals are considered to play an important role in embryonic gut development. Abnormal Hh signaling had been identified in the molecular etiology of the common gastrointestinal tract malformations (GTMs).<sup>7</sup> The family of Hh signaling proteins includes three members: sonic (Shh), Indian (Ihh), and desert (Dhh) hedgehogs. Shh signaling forms the key molecules in gut morphogenesis. These molecules are expressed in the endoderm throughout early embryogenesis and have an important role in gut formation.<sup>8</sup>

In addition to gut development, the Shh signaling pathway is important in neuronal differentiation, axon guidance, and angiogenesis.<sup>9</sup> Astrocytes secrete Shh to promote formation of the blood-brain barrier.<sup>10</sup> A recent study with an in vitro model of retinal vascular endothelial cells demonstrated that the Shh pathway regulates endothelial permeability.<sup>11</sup> A mutation in the Shh pathway may cause a disorder consisting of GTMs and retinal vascular disease.

The aim of this study was to report three unrelated sporadic patients with GTMs exhibiting the FEVR phenotype. Genetic analyses revealed defects in the Shh pathway. This association may necessitate the referral of patients with GTMs to retina specialists.

## Materials and Methods

This was a case series including six eyes of three neonates who underwent routine ophthalmological examination during their hospitalization in the neonatal surgical intensive care unit for GTMs between September 2016 and September 2019. All three of the neonates were male, having gestational ages of 39, 38, and 39 weeks and birth weight of 3500, 3600, and 3300 grams, respectively (Table 1). All were examined by the same ophthalmologist (N.S.K.) using a binocular indirect ophthalmoscope and diagnosed as having FEVR. FEVR was

classified based on ophthalmoscopic findings: stage 1, avascular periphery; stage 2, avascular periphery with neovascularization; stage 3, macula-sparing retinal detachment; stage 4, macula-involving retinal detachment; and stage 5, complete retinal detachment.<sup>12</sup>

Diode laser photocoagulation was performed to 360° presumed avascular areas of retina (0.15 seconds and 160 mW power) in a near confluent pattern, under general anesthesia, in the operating room.

The research was conducted at our tertiary care facility after receiving approval from the local ethics committee (KA19/306). The study complied with the principles of the Declaration of Helsinki. Informed consent form was obtained from the parents of the patients.

### Statistical Analysis

Patient DNA was isolated from whole blood (3 mL) using the QIA amp DNA blood kit (QIAGEN, Hilden, Germany). Three micrograms of high-molecular-weight DNA was sheared using a Covarias ultrasonicator and the genomic DNA library was prepared with an Agilent SureSelect Target Enrichment System. Following enrichment with Agilent SureSelect Human All Exon V7, sequencing was performed on an IlluminaHiSeq 2500 System (Illumina, San Diego, USA). Data interpretation and variant calling were performed on SOPHiA DDM® version 5.4.2 (Sophia Genetics, Switzerland).

## Results

Fundus examination revealed flat neovascularizations and brush-paint-like retinal hemorrhages in all 6 eyes. Figure 1a shows a macular image from patient 1 and Figure 1b shows a presumed avascular area and hemorrhage in the same patient. Fundus images of patient 2 before and after treatment are shown in Figure 1c and 1d. Patient 3 also had hemorrhages as a result of neovascularizations on the border of the vascular zone and presumed avascular retinal regions (Figure 1e,f). All eyes were diagnosed as having stage 2 FEVR without exudation (stage 2A). Presumed avascular areas were treated successfully with laser photocoagulation and no additional treatment was needed. Recurrence was not seen in any case.

Two of the neonates had anal atresia and one had Hirschsprung disease (HSCR). Next, we explored the putative causative mutations associated with the patients' phenotypes. We identified a heterozygous *LRP5* (low-density lipoprotein receptor-related protein 5) mutation (rs80358313, NP\_002326.2:p.Gly610Arg, NM\_002335.4:c.1828G>A) in patient 1 and a heterozygous

**Table 1. Characteristics of the patients**

Patient no, sex	GA (weeks)	BW (g)	LP time (weeks)	Follow-up time (months)	FEVR stage	GTMs
1, male	39	3500	41	56	2A	Anal atresia
2, male	38	3600	40	42	2A	Anal atresia
3, male	39	3300	40	30	2A	Hirschsprung disease

FEVR: Familial exudative vitreoretinopathy, GTMs: Gastrointestinal tract malformations, GA: Gestational age, BW: Birth weight, LP: Laser photocoagulation

*KIF7* (kinesin-like protein *KIF7*) mutation (rs143877028, NP\_940927.2:p.Ser1281Ile, NM\_198525.3:c.3842G>T) in patient 2, who both presented with anal atresia. In patient 3, who had HSCR, we detected a heterozygous *GLI2* (zincfinger protein *GLI2*) mutation (rs751513015, NP\_005261.2:p.Asp705Asn, NM\_005270.4:c.2113G>A). Altogether, our findings demonstrated mutations of different genes in the Shh pathway.

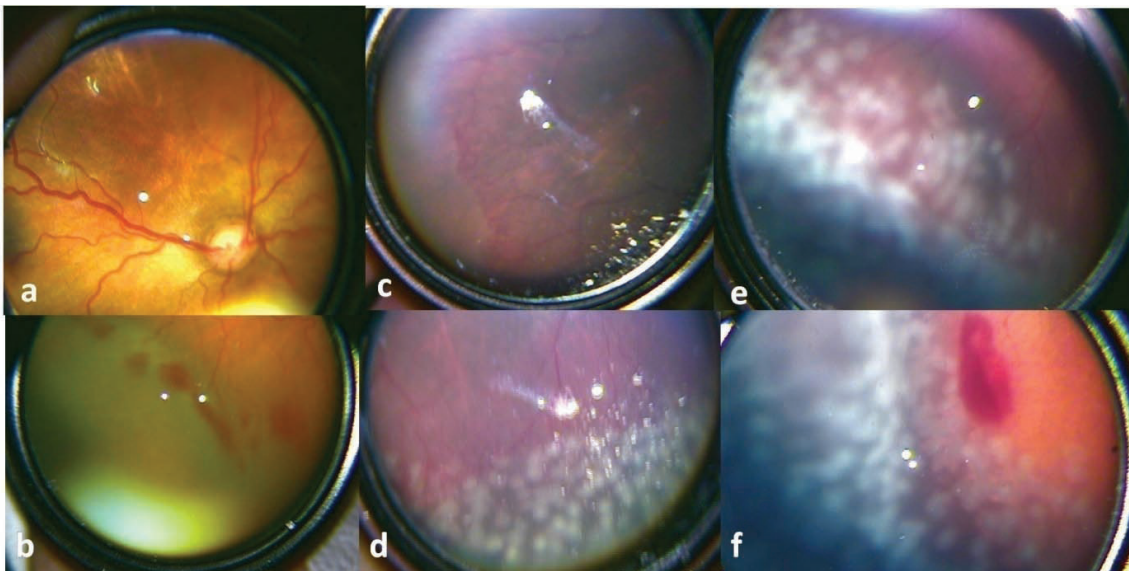
## Discussion

Familial exudative vitreoretinopathy was first defined by Criswick and Schepens<sup>1</sup> in 1969. FEVR presents with varying clinical manifestations but is limited to abnormalities in ocular development.<sup>13</sup> Four genes were found to be associated with FEVR. Autosomal dominant FEVR appears from mutations in *FZD4*, *LRP5*, and *TSPAN12*; the autosomal recessive form occurs in homozygous *LRP5* mutations, and X-linked FEVR arises from mutations in *NDP*.<sup>6</sup> Norrie disease is another hereditary disorder occurring mainly in full-term infants, defined by abnormal retinal vascularization causing retinal detachment. Norrie disease causes blindness soon after birth and most patients have systemic disorders such as mental retardation and deafness.<sup>13</sup> Mutations in the Norrie disease protein (*NDP*) gene leads to Norrie disease.<sup>14</sup> At birth, *NDP* is markedly increased in the retina in order to enhance levels of norrin, which is involved in progenitor proliferation in the postnatal period.<sup>15</sup> McNeill et al.<sup>16</sup> showed that Hh signaling regulates *NDP* expression and concluded that *NDP* is essential downstream of Hh activation to trigger retinal progenitor proliferation in the retina. In addition, Wang et al.<sup>17</sup> showed that Hh signaling is mandatory to support retinal precursor cell proliferation.

Surace et al.<sup>18</sup> investigated the association between the Hh pathway and retinopathy of prematurity (ROP) in murine models and found upregulation of Hh expression similar to vascular endothelial growth factor (VEGF). To support the results, the investigators systemically administered the selective Hh inhibitor cyclopamine in ROP models and revealed that neovascularization was inhibited. Their results proved that Hh pathway activation has an important role in hypoxia-induced retinal neovascularization.

Liu et al.<sup>19</sup> investigated the association between VEGF, retinal neovascularization, and the Hh signaling pathway in murine ROP models. Their results demonstrated that under normal oxygen concentrations, VEGF had low transcription and expression, high oxygen levels stimulated VEGF expression significantly, and cyclopamine inhibited VEGF expression by Hh blockade. The authors hypothesized that the Hh pathway participated in regulating VEGF levels in ROP and that blocking the Hh signaling pathway may be useful in the treatment of ROP.

The *FZD4*, *LRP5*, *TSPAN12*, and *NDP* genes are parts of the Wnt/b-catenin signaling pathway and have roles in cell survival, proliferation, and migration throughout the body. In the current study, an *LRP5* mutation expected in FEVR was found in one patient. However, to our knowledge, this is the first reported case accompanied by anal atresia. Mutations in the *LRP5*, *FZD4*, and *NDP* gene have also been found in patients with ROP at varying frequencies.<sup>20-22</sup> In the current study, we diagnosed the patients as having FEVR based on the clinical presentation and medical data of the neonates, such as gestational age and birth weight. It is difficult to differentiate ROP and FEVR in premature infants. In our cases, the clinical findings mimicked ROP. However, there was no ridge appearance. Instead, all patients had flat



**Figure 1.** Fundus photographs of the patients. **a)** Patient 1, a plus-like appearance is seen in the macular region of the right eye. **b)** Patient 1, retinal hemorrhages and neovascularizations are seen at the border of vascularized and avascular retinal regions of the right eye. **c)** Patient 2, flat neovascularizations are seen in the temporal periphery of the right eye. **d)** Patient 2, fundus appearance after laser photocoagulation in the right eye. **e)** Patient 3, flat neovascularizations and laser spots after treatment in the left eye. **f)** Patient 3, retinal hemorrhage and laser spots after treatment in the left eye

neovascularizations in zone 2 and brush-paint-like hemorrhages. A new classification named ROPER (ROP vs. FEVR) was recently introduced due to the clinical resemblance of these two disorders.<sup>23</sup> John et al.<sup>23</sup> described ROPER in premature infants demonstrating retinal findings more typical of FEVR than ROP. They reported the differentiating fluorescein angiography features of ROPER as irregular buds of vascularization at the vascular/avascular junction, definite pruning of vessels, pinpoint hyperfluorescent areas, and segmental vascular leakage areas. Our patients did not undergo fluorescein angiography, but their retinal findings mimicked ROP. One patient had neovascularization on the iris. The differential diagnosis of these vascular disorders is important, because ROPER may have an unpredictable and long-term course.

In the course of organogenesis, cell numbers are regulated by balancing proliferation and cell death. During development, the Hh signaling pathway controls cell proliferation and survival.<sup>24</sup> Shh is a crucial survival factor for the neural stem cells, midbrain, forebrain, retina, and neural crest.<sup>25,26</sup> Furthermore, a recent study proved that Shh signaling functions in the maintenance of retinal endothelial tight junctions.<sup>11</sup>

Retinal vessels have a high number of pericytes covering the endothelial cells. Signals from pericytes are essential for the formation and maintenance of the blood-retinal barrier.<sup>27</sup> Neovascular vessels are generally associated with disturbance of the blood-retinal barrier. The relationship between Shh signaling and vessel growth and barrier formation demonstrates the role of Shh in angiogenesis and barrier formation. A defect in the Shh pathway is likely to disrupt the blood-retinal barrier, impair oxygen supply to the retina, and cause retinal neovascularization.

HSCR is characterized by functional intestinal obstruction of a genetic etiology.<sup>28</sup> It involves abnormal development of the enteric nervous system resulting in intestinal dysfunction. Congenital anorectal malformations including anal atresia are common manifestations, with an incidence of 1 in 1,000-5,000 neonates.<sup>29</sup> The Hh family proteins (Shh, Ihh, Dhh) are secreted signaling molecules that manage the development and balancing of tissues.<sup>30</sup> Shh, Ihh, and Dhh are all expressed in the gut tube.<sup>30</sup> Gao et al.<sup>31</sup> found that genetic polymorphisms in the Hh gene were associated with HSCR and anorectal malformations. Two of our patients were diagnosed with anal atresia and one was diagnosed with HSCR.

#### Study Limitations

The current study emphasizes the role of the Hh pathway in both retinal vascular and gut development and describes a new syndrome involving FEVR and GTMs. Pediatric surgeons should be aware of this association and refer neonates with GTMs to retina specialists.

#### Conclusion

In future investigations, analysis of clinical findings, retinal imaging with fluorescein angiography, and family genetic analysis may further our understanding of the genetics of neonatal vascular disease.

#### Ethics

**Ethics Committee Approval:** Obtained from the local ethics committee (KA19/306).

**Informed Consent:** Obtained from the parents of all patients.

**Peer-review:** Externally and internally peer reviewed.

#### Authorship Contributions

Concept: N.Ş.K., İ.A., A.T., Ö.K., Design: N.Ş.K., İ.A., A.T., Ö.K., Data Collection or Processing: N.Ş.K., İ.A., A.T., Ö.K., Analysis or Interpretation: N.Ş.K., İ.A., A.T., Ö.K., Literature Search: N.Ş.K., İ.A., A.T., Ö.K., Writing: N.Ş.K., İ.A., A.T., Ö.K.

**Conflict of Interest:** No conflict of interest was declared by the authors.

**Financial Disclosure:** The authors declared that this study received no financial support.

#### References

1. Criswick VG, Schepens CL. Familial exudative vitreoretinopathy. *Am J Ophthalmol.* 1969;68:578-594.
2. Tang M, Sun L, Hu A, Yuan M, Yang Y, Peng X, Ding X. Mutation spectrum of the LRP5, NDP, and TSPAN12 genes in Chinese patients with familial exudative vitreoretinopathy. *Invest Ophthalmol Vis Sci.* 2017;58:5949-5957.
3. Warden SM, Andreoli CM, Mukai S. The Wnt signaling pathway in familial exudative vitreoretinopathy and Norrie disease. *Semin Ophthalmol.* 2007;22:211-217.
4. Gong Y, Slee RB, Fukai N, Rawadi G, Roman-Roman S, Reginato AM, Wang H, Cundy T, Glorieux FH, Lev D, Zacharin M, Oexle K, Marcelino J, Suwairi W, Heeger S, Sabatakos G, Apte S, Adkins WN, Allgrove J, Arslan-Kirchner M, Batch JA, Beighton P, Black GC, Boles RG, Boon LM, Borrone C, Brunner HG, Carle GF, Dallapiccola B, De Paepe A, Floege B, Halfhide ML, Hall B, Hennekam RC, Hirose T, Jans A, Jüppner H, Kim CA, Keppler-Noreuil K, Kohlschütter A, LaCombe D, Lambert M, Lemyre E, Lettboer T, Peltonen L, Ramesar RS, Romanengo M, Somer H, Steichen-Gersdorf E, Steinmann B, Sullivan B, Superti-Furga A, Swoboda W, van den Boogaard MJ, Van Hul W, Vikkula M, Votruba M, Zabel B, Garcia T, Baron R, Olsen BR, Warman ML; Osteoporosis-Pseudoglioma Syndrome Collaborative Group. LDL receptor-related protein 5 (LRP5) affects bone accrual and eye development. *Cell.* 2001;107:513-523.
5. Toomes C, Downey L. Familial exudative vitreoretinopathy, autosomal dominant. 2005 Mar 21 [Updated 2011 Sep 22]. In: Pagon RA, Adam MP, Ardinger HH, editors. *GeneReviews*[Internet] Seattle (WA): University of Washington, Seattle; 1993-2014. Accessed August 8, 2014.
6. Sims KB. NDP-related retinopathies. 1999 Jul 30 [Updated 2009 Jul 23]. In: Pagon RA, Adam MP, Ardinger HH, editors. *GeneReviews*[Internet] Seattle (WA): University of Washington, Seattle; 1993-2014. Accessed August 8, 2014.
7. de Santa Barbara P, van den Brink GR, Roberts DJ. Molecular etiology of gut malformations and diseases. *Am J Med Genet.* 2002;115:221-230.
8. Roberts DJ. Molecular mechanisms of development of the gastrointestinal tract. *Dev Dyn.* 2000;219:109-120.
9. Nagase T, Nagase M, Machida M, Fujita T. Hedgehog signalling in vascular development. *Angiogenesis.* 2008;11:71-77.
10. Alvarez JI, Dodelet-Devillers A, Kebir H, Ifergan I, Fabre PJ, Terouz S, Sabbagh M, Wosik K, Bourbonnière L, Bernard M, van Horssen J, de Vries HE, Charron F, Prat A. The Hedgehog pathway promotes blood-brain barrier integrity and CNS immune quiescence. *Science.* 2011;334:1727-1731.
11. Díaz-Coránquez M, Chao DL, Salero EL, Goldberg JL, Antonetti DA. Cell autonomous sonic hedgehog signaling contributes to maintenance of retinal endothelial tight junctions. *Exp Eye Res.* 2017;164:82-89.



12. Ranchod TM, Ho LY, Drenser KA, Capone A Jr, Trese MT. Clinical presentation of familial exudative vitreoretinopathy. *Ophthalmology*. 2011;118:2070-2075.
13. Shastry B, Hiraoka M, Trese D, Trese M. Norrie disease and exudative vitreoretinopathy in families with affected female carriers. *Eur J Ophthalmol* 1999;9:238-242.
14. Chen ZY, Battinelli EM, Fielder A, Bunday S, Sims K, Breakefield XO, Craig IW. A mutation in the Norrie disease gene (NDP) associated with X-linked familial exudative vitreoretinopathy. *Nat Genet*. 1993;5:180-183.
15. Ye X, Smallwood P, Nathans J. Expression of the Norrie disease gene (Ndp) in developing and adult mouse eye, ear, and brain. *Gene Expr. Patterns*. 2011;11:151-155.
16. McNeill B, Mazerolle C, Bassett EA, Mears AJ, Ringuette R, Lagali P, Picketts DJ, Paes K, Rice D, Wallace VA. Hedgehog regulates Norrie disease protein to drive neural progenitor self-renewal. *Hum Mol Genet*. 2013;22:1005-1016.
17. Wang Y, Dakubo GD, Thuring S, Mazerolle CJ, Wallace VA. Retinal ganglion cell-derived sonic hedgehog locally controls proliferation and the timing of RGC development in the embryonic mouse retina. *Development*. 2005;132:5103-5113.
18. Surace EM, Balaggan KS, Tessitore A, Mussolino C, Cotugno G, Bonetti C, Vitale A, Ali RR, Auricchio A. Inhibition of ocular neovascularization by hedgehog blockade. *Mol Ther*. 2006;13:573-579.
19. Liu M, Chen X, Liu H, Di Y. Expression and significance of the Hedgehog signal transduction pathway in oxygen-induced retinal neovascularization in mice. *Drug Des Devel Ther*. 2018;12:1337-1346.
20. Kondo H, Kusaka S, Yoshinaga A, Uchio E, Tawara A, Tahira T. Genetic variants of FZD4 and LRP5 genes in patients with advanced retinopathy of prematurity. *Mol Vis*. 2013;19:476-485.
21. Dailey WA, Gryc W, Garg PG, Drenser KA. Frizzled-4 variations associated with retinopathy and intrauterine growth retardation: a potential marker for prematurity and retinopathy. *Ophthalmology*. 2015;122:1917-1923.
22. Hutcheson KA, Paluru PC, Bernstein SL, Koh J, Rappaport EF, Leach RA, Young TL. Norrie disease gene sequence variants in an ethnically diverse population with retinopathy of prematurity. *Mol Vis*. 2005;11:501-508.
23. John VJ, McClintic JI, Hess DJ, Berrocal AM. Retinopathy of prematurity versus familial exudative vitreoretinopathy: report on clinical and angiographic findings. *Ophthalmic Surg Lasers Imaging Retina*. 2016;47:14-19.
24. Varjosalo M, Taipale J. Hedgehog: functions and mechanisms. *Genes Dev*. 2008;22:2454-2472.
25. Cai C, Thorne J, Grabel L. Hedgehog serves as a mitogen and survival factor during embryonic stem cell neurogenesis. *Stem Cells*. 2008;26:1097-1108.
26. Stenkamp DL, Frey RA, Mallory DE, Shupe EE. Embryonic retinal gene expression in sonic-you mutant zebrafish. *Dev Dyn*. 2002;225:344-350.
27. Shen W, Fruttiger M, Zhu L, Chung SH, Barnett NL, Kirk JK, Lee S, Coorey NJ, Killingsworth M, Sherman LS, Gillies MC. Conditional Müller cell ablation causes independent neuronal and vascular pathologies in a novel transgenic model. *J Neurosci*. 2012;32:15715-15727.
28. Amiel J, Sproat-Emison E, Garcia-Barcelo M, Lantieri F, Burzynski G, Borrego S, Pelet A, Arnold S, Miao X, Griseri P, Brooks AS, Antinolo G, de Pontual L, Clement-Ziza M, Munnich A, Kashuk C, West K, Wong KK, Lyonnet S, Chakravarti A, Tam PK, Ceccherini I, Hofstra RM, Fernandez R; Hirschsprung Disease Consortium. Hirschsprung disease, associated syndromes and genetics: a review. *J Med Genet*. 2008;45:1-14.
29. Rintala RJ. Congenital anorectal malformations: Anything new? *J Pediatr Gastroenterol Nutr*. 2009;48:7982.
30. McMahon AP, Ingham PW, Tabin CJ. Developmental roles and clinical significance of hedgehog signaling. *Curr Top Dev Biol*. 2003;53:1114.
31. Gao H, Wang D, Bai Y, Zhang J, Wu M, Mi J, Jia H, Wang W. Hedgehog gene polymorphisms are associated with the risk of Hirschsprung's disease and anorectal malformation in a Chinese population. *Mol Med Rep*. 2016;13:4759-4766.