



# Causes, Treatment, and Outcome in Private School Children Admitted to Emergency Department with Eye Trauma

## Göz Travması Sebebiyle Acil Servise Başvuran Özel Okul Çocuklarında Sebepler, Tedavi ve Prognoz

Aydın Yıldırım\*, A. Haşim Uslu\*, Hatice Nur Çolak\*, Bülent Gürler\*

\*Fatih University Faculty of Medicine, Department of Ophthalmology, İstanbul, Turkey

### Summary

**Objectives:** To analyze the causes, treatment, and outcome in the private school children admitted to emergency department (ED) for eye injury.

**Material and Methods:** The recordings of 57 children with eye traumas were examined retrospectively. Examination, treatment, and follow-up files of the children were recorded.

**Results:** The age of the 57 children varied between 8 and 16 years. The trauma causes were impact during playing in 35.1% (20) of cases, hit by ball in 31.5% (18) of cases, injury by paper objects in 7.1% (4) of cases, injury by pencil in 5.3% (3) of cases, and injuries by other foreign objects (glass, rubber, branch of tree, and racket) in 21.0% (12) of cases. Cornea erosion in 54.3% (31) of cases, conjunctival erosion and irritation in 19.2% (11) of cases, eyelid laceration in 8.8% (5) of cases, subconjunctival hemorrhage in 8.8% (5) of cases, eyelid edema in 5.3% (3) of cases, hyphema in 1.8% (1) of cases, and iridocyclitis in 1.8% (1) of cases were found. Repair of eyelid was performed in 3 cases.

**Conclusion:** Eye traumas are very commonly seen in private school children. While most of the cases are simple injuries, significant problems such as lid lacerations that necessitate repair can also encountered in a few cases. A fast and efficient treatment usually minimizes the risk of sequel development. (Turk J Ophthalmol 2014; 44: 216-8)

**Key Words:** Eye trauma, children, prognosis

### Özet

**Amaç:** Göz travması sebebiyle acil servise getirilen özel ilköğretim çağı çocuklarında travma sebepleri, tedavi ve prognozun değerlendirilmesi.

**Gereç ve Yöntem:** Göz travması sebebiyle acil servise başvuran 57 özel ilköğretim çağı çocuğuna ait veriler retrospektif olarak araştırıldı. Göz muayene bulguları, tedavi ve takip verileri değerlendirildi.

**Bulgular:** Elli yedi çocuğun yaşları 8 ile 16 yıl arasında değişmektedir. Travma sebepleri incelendiğinde, oyun esnasında darbe 20 olguda (%35,1), top çarpması 18 olguda (%31,5), kağıt ile yaralanma 4 olguda (%7,1), kalem ile yaralanma 3 olguda (%5,3) ve diğer yabancı cisimler (cam, silgi, ağaç dalı ve raket) ile yaralanma 12 olguda (%21,0) saptandı. Bu olguların göz muayenelerinde, kornea erozyonu 31 olguda (%54,3), konjonktiva erozyonu ve tahrişi 11 olguda (%19,2), göz kapağı yaralanması 5 olguda (%8,8), konjonktiva altı kanama 5 olguda (%8,8), göz kapağı ödemi 3 olguda (%5,3), hifema 1 olguda (%1,8) ve travmatik iridosiklit 1 olguda (%1,8) gözlemlendi. Göz kapağı tamiri 3 olguda (%5,3) yapıldı.

**Sonuç:** Özel ilköğretim çağı okul çocuklarında göz travması sıklıkla gelişebilmektedir. Olguların büyük bir bölümünde basit göz yaralanması gelişirken, az bir kısmında tamir gerektirecek kadar geniş kapak kesisi ile karşılaşılabilmektedir. Olguların hızlı ve etkili tedavi edilmesi sekel gelişmesi olasılığını azaltabilmektedir. (Turk J Ophthalmol 2014; 44: 216-8)

**Anahtar Kelimeler:** Göz travması, çocuk, prognoz

## Introduction

Ocular trauma remains an important topic in ophthalmology due to its high prevalence during childhood. The percentage of pediatric ocular trauma among patients attending the ophthalmology department during a period of 1 year was 4.0%.<sup>1,2</sup> Additionally, even though any age group can have eye injuries, the eye injuries of children <18 years account for 35%-50% of all eye injuries.<sup>3-5</sup> Moreover, 10 per 10.000 children <18 years carry eye trauma risks.<sup>5</sup> This high ratio necessitates a closer assessment of the epidemiological data of the childhood eye trauma studies.

In this study, the causes, treatment and prognosis of eye traumas in private school children admitted to emergency department (ED) have been examined to make a contribution to the epidemiological data in this field.

## Materials and Methods

This study was made by assessing the patient files retrospectively. For this purpose, we evaluated the electronic files of primary school children from 3 private schools, who, following an emergency examination in the ED due to eye trauma, were referred to the ophthalmology department at Fatih University Medical School Hospital between December 2006 and April 2012. The patient data were prepared with reference to their age group, sex, the traumatized eye, trauma type, examination findings, treatment, and outcome.

This study was adhered to the tenets of Declaration of Helsinki. Informed consent was obtained from all patients.

All statistical tests were performed using SPSS (Statistical Package for the Social Sciences; SPSS Inc., Chicago, IL, USA) version 16.0. Mann-Whitney U-test and chi-square test were used for the statistical analyses. P-value of <0.05 was considered statistically significant.

## Results

Fifty-seven private school children were included in the study. There were 44 boys (77.1%) and 13 girls (22.9%). Injured children ranged in age from 8 to 16 years (mean±SD, 12.64±2.55 years) (Figure 1). The mean ages of boys and girls were 12.7±2.5 and 13.4±1.7 years, respectively (p=0.313). Boys sustained significantly more eye injuries than girls (3.4/1). Twenty-nine (51%) right eyes and 28 (49%) left eyes were injured. Twenty right eyes and 24 left eyes were injured in the boys, while 10 right eyes and 3 left eyes were injured in the girls (p=0.061).

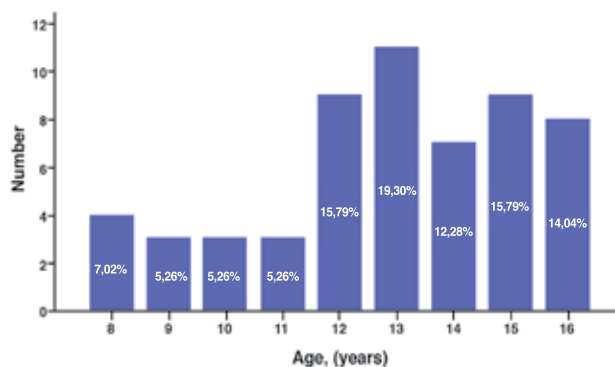
As all schools were in the same neighborhood with the hospital, all children were brought to the ED in a couple of hours following the trauma. The trauma reasons were impact during playing in 35.1% (20) of cases, hit by ball in 31.5% (18) of cases, injury by paper objects in 7.1% (4) of cases, injury by pencil in 5.3% (3) of cases, and injuries by other foreign objects (glass, rubber, branch of tree, and racket) in 21.0% (12) of cases. The most common causes of pediatric injuries were impact during playing games or hit by ball (66.6%) (Table 1).

The following problems were detected as a result of the detailed eye examination of the cases referred to the ophthalmology department following their general examination in the ED: Cornea erosion in 54.3% (31) of cases, conjunctival erosion and irritation in 19.2% (11) of cases, eyelid laceration in 8.8% (5) of cases, subconjunctival hemorrhage in 8.8% (5) of cases, eyelid edema in 5.3% (3) of cases, hyphema in 1.8% (1) of cases, and traumatic iridocyclitis in 1.8% (1) of cases (Table 2). No severe problems such as globe perforation or retinal detachment were observed. Cornea erosion was the most common type of the eye injury (54.3%).

All of the patients were treated as outpatients. Therapeutic bandage lens was applied in 5 cases with wide cornea erosion until the epithelium recovery was completed. Simple occlusion was preferred in other cases. Cases, who had conjunctival erosion and irritation, recovered in a couple of days with only medical treatment. The repair of eyelid under local anesthesia was

	<b>n (%)</b>
Impact during playing	20 (35.1)
Hit by ball	18 (31.5)
Paper	4 (7.1)
Pencil	3 (5.3)
Others (glass, rubber, branch of tree, racket)	12 (21.0)

	<b>n (%)</b>
Cornea erosion	31 (54.3)
Conjunctival erosion/irritation	11 (19.2)
Eyelid laceration	5 (8.8)
Subconjunctival hemorrhage	5 (8.8)
Eyelid edema	3 (5.3)
Hyphema	1 (1.8)
Iridocyclitis	1 (1.8)



**Figure 1.** Age distributions of children

performed in 3 cases with deep cuts. The other 2 cases with eyelid lacerations were followed with medical treatment.

Subconjunctival hemorrhage cases recovered eventually within a couple of weeks. The cases with eyelid edema recovered completely in a few days.

The cases with microscopic hyphema in the anterior chamber were treated medically and recovered without sequel within a month. The cases with traumatic iridocyclitis recovered completely in 3 weeks with medical treatment.

The remaining cases recovered easily within days with simple medical treatments.

## Discussion

Since they are frequently seen in childhood and may cause significant visual impairment, eye traumas need to be carefully assessed with reference to their epidemiological data.<sup>1,5</sup> In this study, conducted with this objective in mind, the data of 57 children who were admitted to the ED due to eye trauma and later were treated and followed by the ophthalmology unit were examined. In our study, among the children exposed to eye traumas, the number of boys was 3.4 times higher. The same ratio was documented in similar study among Egyptian school children.<sup>2</sup> There are other studies showing a clearly higher prevalence among boys.<sup>3-9</sup> The higher rate of eye trauma among boys, compared to girls, is owed to their active nature and game type and playing preferences.

Our cases revealed a similar ratio for the traumatization of right and left eyes. However, in the literature, there are a variety of data with regard to the traumatized eye.<sup>7,8</sup>

The duration between the trauma incidence and initiation of treatment is directly correlated with the prognosis.<sup>2,8,10</sup> The fact that the schools of the children brought to our ED for eye trauma were both very close to our hospital enabled early treatment in all cases.

In 66.6% of our cases, the trauma reasons were impact during game playing and getting hit by ball. A wide-scale study evaluating children admitted to EDs in the USA during a 20-year period shows that eye trauma during ball games accounts for the most common trauma cause with 25%.<sup>5</sup> A higher share of boys within the patient population is observed and their game preferences play a significant role in the frequency of this reason.

Eye traumas may be seen in a wide spectrum varying from simple conjunctival irritation to globe perforation.<sup>2,5,8,11</sup> In most cases, the trauma remains at cornea and conjunctival erosion level, where no hospitalization is needed and no vision loss is observed.<sup>5,12</sup> Similarly, in most of our cases (73.5%), the eye injuries such as cornea erosion and conjunctival erosion were at a mild level. The cases were treated on the same day as outpatients.

Even though eyelid lacerations wide enough to necessitate repairs were observed in 3 patients, severe eye injuries such as globe perforation were not detected. The studies reveal an inverse correlation between the severity of the trauma-related eye injuries and the socioeconomic status of the parents.<sup>3,13</sup> Likewise, according to the study by Keklikci et al.<sup>14</sup>, as the parental education and income level falls, the incidence of perforated eye injuries increases. The milder nature of the eye injuries in the majority of our study group has a close relationship with the higher socioeconomic level of the parents. Hence, all cases are pupils from 3 private schools.

Consequently, eye traumas are frequently seen in private school children. While most of the cases are simple eye injuries, few patients present with more significant problems such as hyphema and eyelid lacerations wide enough to necessitate repair. Fast and efficient treatment of the cases minimizes the sequel risks.

The possibility of exposure to traumas might be reduced due to the fact that most of the injuries occurred during game playing with a supervisor observing and advising the children to be more careful.

## References

- Dandona L, Dandona R, Srinivas M, John RK, McCarty CA, Rao GN. Ocular trauma in an urban population in Southern India: the Andhra Pradesh Eye Disease Study. *Clin Experiment Ophthalmol*. 2000;28:350-6.
- El-Sebaity DM, Soliman W, Soliman AMA, Fathalla AM. Pediatric Eye Injuries in Upper Egypt. *Clin Ophthalmol*. 2011;5:1417-23.
- Moreira CA Jr, Debert-Ribeiro M, Belfort R Jr. Epidemiological study of eye injuries in Brazilian children. *Arch Ophthalmol*. 1988;106:781-4.
- Karshioğlu S, Hacıbekiroğlu A, Tamsel S, Tumsen D, Ziyilan S, Akmut T. Epidemiologic evaluation of eye traumas. *Turk J Ophthalmol*. 2001;3:484-91.
- Pollard KA, Xiang H, Smith GA. Pediatric Eye Injuries Treated in US Emergency Departments, 1990-2009. *Clin Pediatr (Phila)*. 2012;51:374-81.
- Gokyigit B, Akar S, Ozturk A, Yılmaz OF. Isolated eye traumas in childhood. *Turk J Ophthalmol*. 2005;35:155-62.
- Oner A, Kekec Z, Karakucuk S, İkizceli I, Sözüter EM. Ocular trauma in Turkey: a 2-year prospective study. *Adv Ther*. 2006;23:274-83.
- Gumus K, Topaktas D, Arda H, et al. Clinical and demographic properties of penetrating eye injuries occurred in childhood. *Türkiye Klinikleri J Ophthalmol*. 2009;18:7-12.
- Turgut S, Perente I, Ozgun C, Ovalı T, Ongor E. Pediatric penetrating eye traumas: Risk factors. *Turkish Journal of Trauma Emergency Surgery*. 1997;3:58-61.
- Acar U, Tok OY, Acar DE, Burcu A, Ornek F. Epidemiological and clinical evaluation of open-globe injuries in childhood. *Turk J Ophthalmol*. 2010;40:62-6.
- Wong TY, Klein BE, Klein R. The prevalence and 5-year incidence of ocular trauma. The Beaver Dam Eye Study. *Ophthalmology*. 2000;107:2196-202.
- McGwin G Jr, Owsley C. Incidence of emergency department-treated eye injury in the United States. *Arch Ophthalmol*. 2005;123:662-6.
- Arıturk N, Sahin M, Oge I, Erkan D, Sullu Y. The evaluation of ocular trauma in children between ages 0-12. *Turk J Pediatr*. 1999;41:43-52.
- Keklikci U, Sakalar YB, Unlu K, Bozarslan BS, Dag U. Importance of the family factor in perforating eye injuries. *Turk J Ophthalmol*. 2001;37:474-9.